

# Scapular Dyskinesia and Its Relation to Shoulder Pain

W. Ben Kibler, MD, and John McMullen, ATC

## Abstract

Scapular dyskinesia is an alteration in the normal position or motion of the scapula during coupled scapulohumeral movements. It occurs in a large number of injuries involving the shoulder joint and often is caused by injuries that result in the inhibition or disorganization of activation patterns in scapular stabilizing muscles. It may increase the functional deficit associated with shoulder injury by altering the normal scapular role during coupled scapulohumeral motions. Scapular dyskinesia appears to be a nonspecific response to shoulder dysfunction because no specific pattern of dyskinesia is associated with a specific shoulder diagnosis. It should be suspected in patients with shoulder injury and can be identified and classified by specific physical examination. Treatment of scapular dyskinesia is directed at managing underlying causes and restoring normal scapular muscle activation patterns by kinetic chain-based rehabilitation protocols.

J Am Acad Orthop Surg 2003;11:142-151

The understanding of shoulder function in throwing or work activities and of shoulder dysfunction after injuries has focused on (1) describing how the humerus moves in relation to the glenoid, (2) how the glenohumeral ligaments and labrum statically constrain humeral translation, and (3) how the rotator cuff dynamically constrains glenohumeral motion. The entire scapula, not just the glenoid, is intimately involved in all of these functions, but its specific involvement is underemphasized, especially as a dynamic contributor to shoulder/arm function and dysfunction. Alterations in scapular position and motion occur in 68% to 100% of patients with shoulder injuries.<sup>1</sup> Specific information about the role of the scapula can help the clinician understand and treat shoulder injuries. Knowledge of scapular kinematics, function, and evaluation is growing, and understanding the

role of the scapula in shoulder function and dysfunction is evolving. Both basic research and clinical studies have served to define normal shoulder function, scapular dyskinesia, methods of classification, evaluation techniques, and rehabilitation methods.

## Normal Scapular Function

The scapula is anatomically and biomechanically intimately involved with shoulder function. During the process of shoulder and arm movement to achieve a change in glenohumeral position as well as during motions required for athletic and daily activities, the two are linked. The scapula, shoulder, and arm are either stabilized in or move to certain positions to generate, absorb, and transfer forces that accomplish work or athletic tasks. Alterations of scapular position at rest, or with

coupled arm motion, are commonly associated with injuries that create clinical dysfunction of the shoulder. These alterations, which may be the result of injury or may exacerbate an existing injury (and thus may increase symptoms), are called scapular dyskinesia,<sup>1</sup> a general term describing the loss of control of scapular motion and position seen clinically. The term does not suggest etiology or define patterns that correlate with specific shoulder injuries. Classification of scapular dyskinesia patterns and positions can help to determine treatment.

A primary role of the scapula is that it is integral to the glenohumeral articulation, which kinematically is a ball-and-socket configuration. To maintain this configuration, the scapula must move in coordination with the moving humerus so that the instant center of rotation, the mathematical point within the humeral head that is the axis of rotation of the glenohumeral joint, is constrained within a physiologic pattern throughout the full range of shoulder mo-

---

Dr. Kibler is Medical Director, Lexington Sports Medicine Center, Lexington, KY. Mr. McMullen is Manager, Sports Medicine and Physical Therapy, Lexington Sports Medicine Center.

Reprint requests: Dr. Kibler, 1221 South Broadway, Lexington, KY 40504.

Copyright 2003 by the American Academy of Orthopaedic Surgeons.

---

tion.<sup>2,3</sup> Proper alignment of the glenoid allows optimum function of both the bony constraints and the muscles of the rotator cuff, allowing concentric glenohumeral motion.<sup>4,5</sup>

The second role of the scapula is to provide motion along the thoracic wall. The scapula retracts (externally rotates) to facilitate the position of cocking.<sup>6</sup> This cocking position is important in the baseball throw, the tennis serve, and the swimming recovery. As acceleration proceeds, the scapula must protract laterally (internally rotate) in a smooth fashion, then anteriorly around the thoracic cage, to maintain a normal position in relation to the humerus and to dissipate some of the deceleration forces that occur in follow-through as the arm goes forward.<sup>4,6,7</sup> In workers, scapular retraction creates a stable base for the abducted or elevated arm to do tasks that require reaching, pushing, or pulling.

The first two roles (glenohumeral articulation and motion along the thoracic wall) confer a coupled interdependency between movements of the arm and scapula that creates dynamic stability for the glenohumeral joint in the positions and motions of athletic or work activities.<sup>3,7</sup> This dynamic relationship has been compared to a ball on a seal's nose. (The seal's nose must move to keep the ball from falling off.)

The third role that the scapula plays in shoulder function is elevation of the acromion, which occurs during the cocking and acceleration phases of throwing or arm elevation, to clear the acromion from the moving rotator cuff to decrease impingement and coracoacromial arch compression.<sup>8,9</sup> Although rotator cuff fatigue may cause superior humeral head migration to trigger subacromial impingement in this position,<sup>10</sup> lower trapezius and serratus anterior muscle fatigue also may contribute to impingement by decreasing acromial elevation.<sup>11</sup>

The final role that the scapula plays in shoulder function is as a link in proximal-to-distal sequencing of velocity, energy, and forces of shoulder function.<sup>10,12,13</sup> For most activities, sequencing begins at the ground, and individual body segments (links) are coordinated by muscle activation and body position to generate, summate, and transfer force through these segments to the terminal link. This sequence is termed the kinetic chain.<sup>10,12,14</sup> These serial muscle activation patterns stabilize the scapula and increase the control of its motion and position as the arm is moved. The scapula is thus pivotal in transferring large forces and high energy from the legs, back, and trunk to the delivery point, the arm and the hand,<sup>12-15</sup> thereby allowing more force to be generated in activities such as throwing than could be done by the arm musculature alone. The scapula, serving as a link, also stabilizes the arm to more effectively absorb loads that may be generated through the long lever of the extended or elevated arm.<sup>7</sup>

### Scapular Dyskinesia

Scapular dyskinesia<sup>1</sup> is defined as observable alterations in the position of the scapula and the patterns of scapular motion in relation to the thoracic cage. Several factors may create these abnormal patterns and positions.

#### Bony Posture or Injury

A resting posture of excessive thoracic kyphosis and increased cervical lordosis can result in excessive scapular protraction and acromial depression in all phases of athletic activity, increasing the potential for impingement.<sup>6,8</sup> Fractures of the clavicle can shorten or angulate the strut, which helps maintain proper scapular position. Acromioclavicular joint injuries, instabilities, or arthrosis also interfere with clavicular

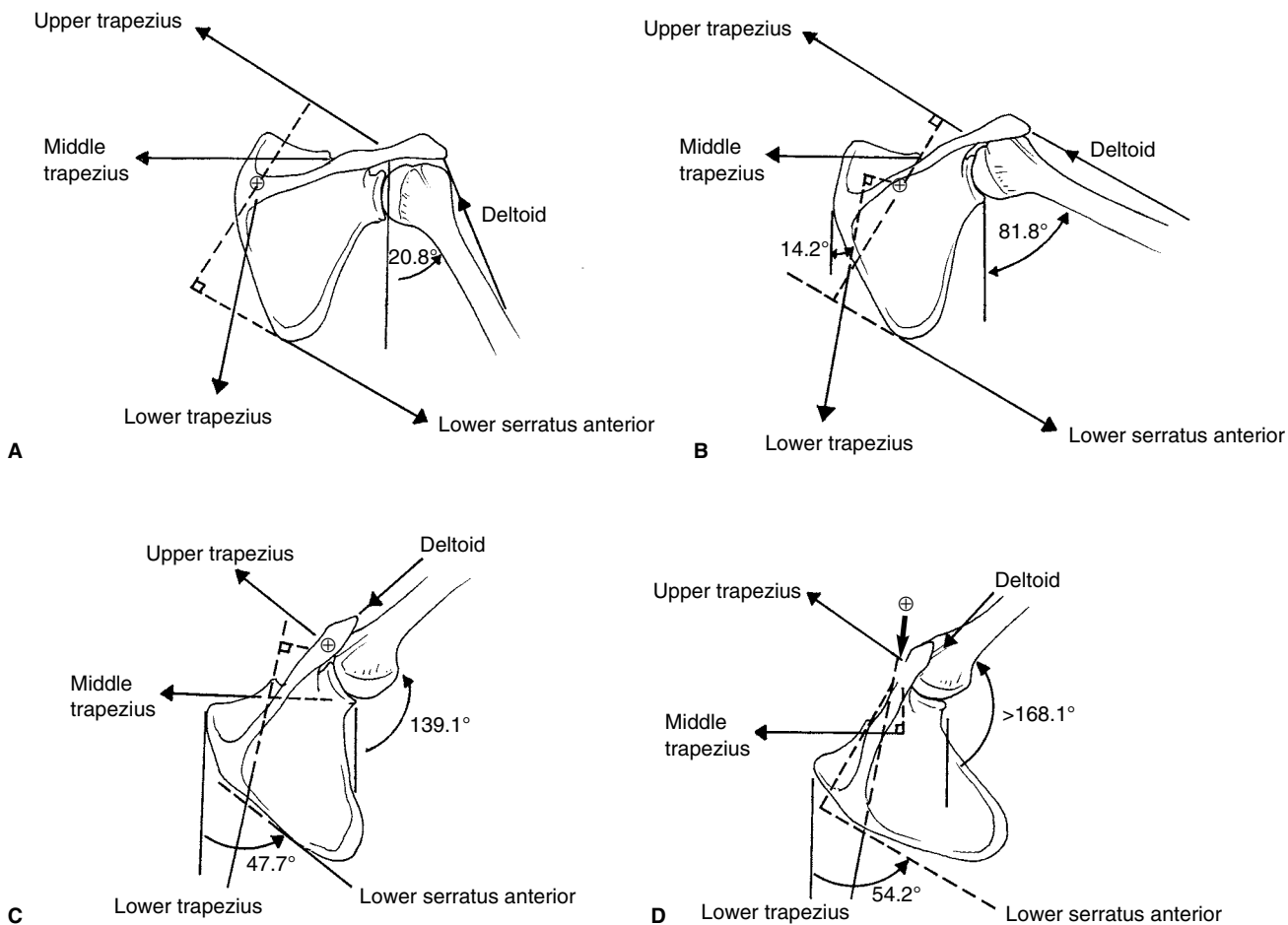
strut function and can alter scapular kinematics by not allowing the normal progression of the instant center of scapular rotation from the medial scapular border to the acromioclavicular joint.<sup>3,16</sup>

#### Alteration in Muscle Function

Scapular dyskinesia most frequently occurs as a result of alteration of muscle activation or coordination. The motion of the scapula results from patterned muscle activation and passive positioning resulting from trunk and arm acceleration. The muscle activation patterns result in force couples for scapular control<sup>5,7,17,18</sup> (Fig. 1). Scapular stabilization requires coupling of the upper and lower trapezius and rhomboid muscles with the serratus anterior muscle. Scapular elevation involves the serratus anterior and lower trapezius muscles coupled with the upper trapezius and rhomboid muscles.<sup>17</sup> Lower trapezius activation is especially important in maintaining the normal path of the instant center of scapular motion in arm elevation. This results from the mechanical advantage of its attachment at the medial aspect of the scapular spine and to its straight line of pull as the arm elevates and the scapula rotates.<sup>18</sup>

Most nonphysiologic motion and thus abnormal mechanics that occur with the scapula can be traced to alterations in the function of the muscles that control it.<sup>11,18-21</sup> Injury to the long thoracic nerve can alter muscular function of the serratus anterior muscle, and injury to the spinal accessory nerve can alter function of the trapezius muscle, causing abnormal stabilization and control, which occurs in approximately 5% of cases.

More commonly, the scapular stabilizing muscles (1) are directly injured from direct-blow trauma; (2) have microtrauma-induced strain in the muscles, leading to muscle weakness; (3) become fatigued from repet-



**Figure 1** Force couples for scapular rotation. In early coupled arm elevation/scapular rotation (A and B), the upper and lower trapezius and serratus anterior muscles have long moment arms and are effective rotators and stabilizers. With higher arm elevation (C), the upper trapezius moment arm is shorter, while the lower trapezius and serratus anterior moment arms remain long and continue to rotate the scapula. With maximum arm elevation (D), the lower trapezius is ideally placed to maintain scapular position and pull along its long axis. As a result of these activities, the scapular instant center of rotation (⊕) moves from the medial border of the spine to the acromioclavicular joint. (Adapted with permission from Bagg SD, Forrest WJ: A biomechanical analysis of scapular rotation during arm abduction in the scapular plane. *Am J Phys Med Rehabil* 1988;67:238-245.)

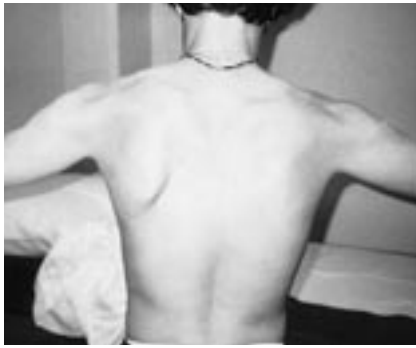itive tensile use; or (4) are inhibited by painful conditions around the shoulder. Muscle inhibition or weakness is quite common in glenohumeral pathology, whether from instability, labral pathology, or arthrosis.<sup>10,11,19,21</sup> The serratus anterior and the lower trapezius muscles are the most susceptible to the effect of the inhibition, and they are more frequently involved in early phases of shoulder pathology.<sup>4,6,11</sup> Muscle inhibition and resulting scapular dyskinesia appear to be a nonspecific response to a painful condition in the

shoulder rather than a specific response to a certain glenohumeral pathology. This fact is supported by the finding of scapular dyskinesia in as many as 68% of patients with rotator cuff abnormalities, 94% with labral tears, and 100% with glenohumeral instability problems.<sup>1,22,23</sup> Inhibition is seen as a decreased ability of the muscles to exert torque and stabilize the scapula as well as disorganization of the normal muscle firing patterns of the muscles around the shoulder.<sup>4,11,21</sup> The exact nature of this inhibition is not clear. The

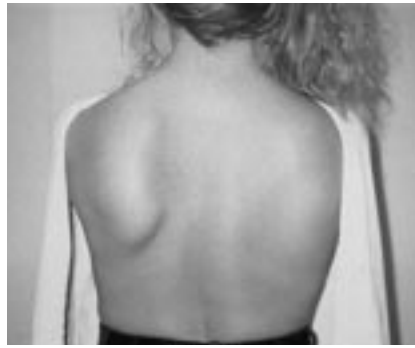nonspecific response and the disorganization of motor patterns suggest a proprioceptively based mechanism. Pain, either from direct or indirect muscle injury, and fatigue or uncontrolled muscle strain, have been shown to alter proprioceptive input from Golgi tendon organs and muscle spindles.

#### Contractures and Other Flexibility Problems

Inflexibility or contracture of the muscles and ligaments around the shoulder can affect the position and



A



B

**Figure 2** A, Type I dyskinesia, with inferior medial border prominence (left scapula). B, Type II dyskinesia, with prominence of the entire medial border (left scapula).

motion of the scapula. Tightness in the pectoralis minor or in the short head of the biceps, both of which attach to the coracoid process, can create an anterior tilt and forward pull on the scapula. Lack of full internal rotation of the glenohumeral joint, caused by capsular or muscular tightness, affects the normal motion of the scapulothoracic articulation.<sup>6,23-25</sup> This creates a “wind up” effect so that the glenoid and scapula are pulled in a forward inferior direction by the moving rotating arm.<sup>6</sup> This can create an excessive amount of protraction of the scapula on the thorax as the arm continues into an adducted position in follow-through during throwing or into forward arm elevation in working. Because of the ellipsoid geometry of the upper portion of the thorax, the scapula moves disproportionately anteriorly and inferiorly around the thorax with more scapular protraction.<sup>9,26</sup>

### Classification of Scapular Dyskinesia

Three-dimensional biomechanical analysis of possible scapular motions shows that the scapula moves around three axes of motion simultaneously.<sup>6,11</sup> Patterns of abnormal

motion in scapular dyskinesia are best observed by first determining the position of the scapula with the patient’s arms at rest at the side, then by observing the scapular motion as the arms are elevated and lowered in the scapular plane. These dyskinetic patterns fall into three categories, which correspond to the three planes of motion on the ellipsoid thorax.<sup>27</sup> This system can help identify the type of abnormal scapular motion and thus the rehabilitation required by muscle strengthening and restoration of flexibility. Type I (Fig. 2, A) is characterized by prominence of the inferior medial scapular border. This motion is primarily abnormal rotation around a transverse axis. Type

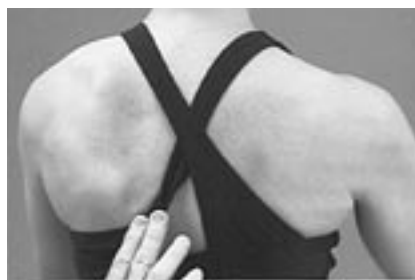II (Fig. 2, B) is characterized by prominence of the entire medial scapular border and represents abnormal rotation around a vertical axis. Type III (Fig. 3) is characterized by superior translation of the entire scapula and prominence of the superior medial scapular border. The net effect of the scapular dyskinetic patterns is an adverse effect on the normal role of the scapula in shoulder function.<sup>28</sup>

### Effects of Scapular Dyskinesia

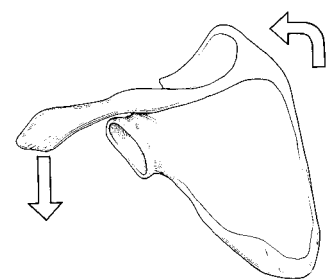
#### Loss of Retraction/Protraction Control

Lack of full scapular retraction causes loss of the stable cocking point in throwing or loss of the stable base in arm elevation.<sup>3</sup> Lack of full scapular protraction around the thoracic wall increases the deceleration forces in the shoulder joint<sup>5,29</sup> and causes changes in the normal safe zone relationship between the glenoid and humerus as the arm moves through the acceleration phase.<sup>3,4,7</sup> Too much protraction because of tightness in either the joint capsule or the anterior coracoid muscles will cause impingement as the scapula rotates down and forward.<sup>8,9,16,17,24,25</sup>

Loss of protraction control also creates functional anteversion of



A



B

**Figure 3** A, Type III dyskinesia, with prominence of the superior medial border (left scapula). B, Scapular superior translation on the thorax.

the glenoid, decreasing the normal bony buttress to anterior translation. This may increase the shear stresses on the rest of the anterior stabilizing structures—the labrum and glenohumeral ligaments—thus increasing the risk of shear injury or strain.<sup>30</sup> Posteriorly, this anteversion increases the degree of impingement between the posterior superior glenoid and posterior rotator cuff<sup>23</sup> by moving the posterior aspect of the glenoid closer to the externally rotated and horizontally abducted arm.

### Loss of Elevation Control

Loss of ability to elevate the acromion can be a secondary source of impingement in other shoulder problems, such as glenohumeral instability.<sup>9,21,23,31</sup> The serratus anterior and especially the lower trapezius appear to be the first muscles involved in inhibition-based muscle dysfunction.<sup>4,11</sup> Lack of acromial elevation and consequent secondary impingement can be seen early in many shoulder problems, such as rotator cuff tendinitis and glenohumeral instability. This can play a role in the development of further symptoms.<sup>9,10,22</sup>

### Loss of Kinetic Chain Function

One of the most important abnormalities in scapular biomechanics is the loss of the link function in the kinetic chain. If scapular motion is impaired, the forces generated from the lower extremity and trunk will not be effectively transmitted to the upper extremity.

### Evaluation

Scapular evaluation should include distant contributions to normal scapular function and dyskinesia. Similarly, dynamic evaluation of motion, muscular activation, and corrective maneuvers should be done.

Leg and trunk muscle activity is important<sup>12,15,29</sup> in shoulder and arm throwing, serving, and lifting activities and as a major source of facilitation of scapular muscle activation.<sup>26</sup> Lumbar lordosis, pelvic tilt, and hip rotational abnormalities should be checked.

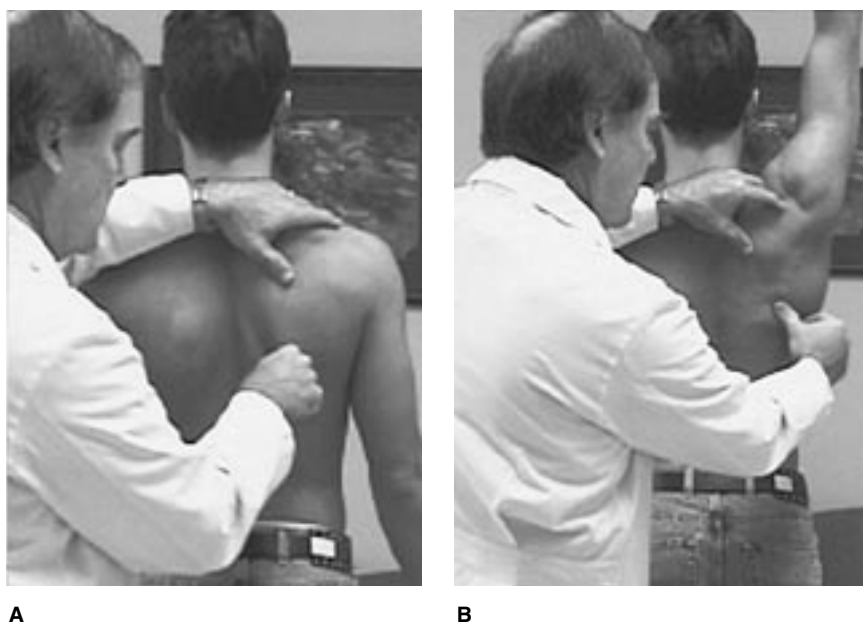
Thoracic and cervical posture should be evaluated because increased thoracic kyphosis or scoliosis may have a direct effect on the motion of the scapula by creating an abnormal surface contour for scapular motion. Excessive cervical lordosis may indicate posterior cervical muscle or fascia tightness or anterior clavicular fascia tightness, which can affect scapular retraction and protraction.

The evaluation of the scapula itself should be done mainly from the posterior aspect (Figs. 4-6). Scapular position may be evaluated in several ways. Abnormalities of winging, elevation, or rotation may first be examined in the resting posi-

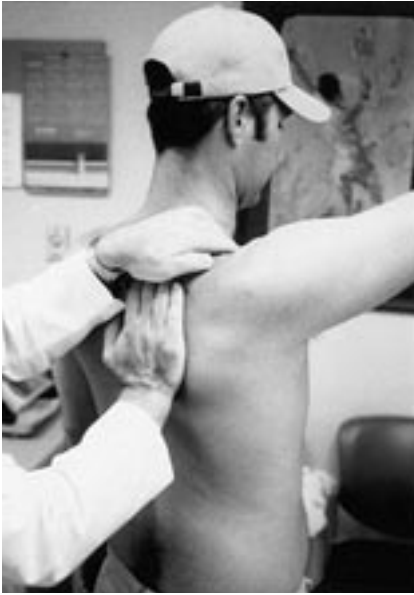tion. In long-standing scapular dyskinesia, resting winging may be seen. Pure serratus anterior muscle weakness resulting from nerve palsy will create a prominent superior medial border and depressed acromion, whereas pure trapezius muscle weakness resulting from nerve palsy will create a protracted inferior border and elevated acromion.<sup>20</sup>

There may be pain to palpation over the anterior shoulder at the coracoid tip, secondary to adaptive tightness and scar in the pectoralis minor muscle and the short head of the biceps. In addition, the superior or entire medial border may be painful to palpation or with motion because of similar tightness or scar in the levator scapulae or lower trapezius insertions, or both. Finally, there may be trigger points, areas of tenderness in the body of the upper trapezius muscle.

Motion and position should be examined in both the elevating and lowering phases of motion. Muscle



**Figure 4** Scapular assistance test. The examiner assists serratus anterior and lower trapezius muscle activity as the arm is elevated. Relief of impingement symptoms is a positive test. **A**, Examiner's right hand position at start of test. **B**, Assisted scapular rotation with arm elevation.



**Figure 5** Scapular retraction test. The examiner stabilizes the medial scapular border as the arm is elevated or externally rotated. Relief of impingement symptoms is a positive test.

weakness and mild scapular dyskinesis are more common in the lowering phase of arm movement. These commonly present as a hitch or a jump in the otherwise smooth motion of the scapula or scapular border and may be more noticeable with several repetitions of the motion.

An effective maneuver for evaluating scapular muscle strength is an isometric pinch of the scapulas in retraction. Scapular muscle weakness may manifest as a burning pain in less than 15 seconds, whereas the scapula normally may be held in this position for 15 to 20 seconds without burning pain or muscle weakness. Wall push-ups are effective for evaluating serratus anterior muscle strength. Abnormalities of scapular winging may be noted with 5 to 10 wall push-ups.

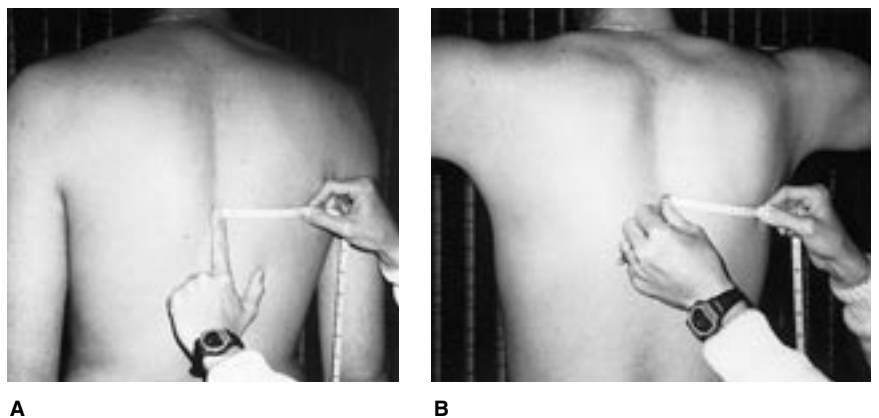
The scapular assistance test (Fig. 4) evaluates scapular and acromial involvement in subacromial impingement. In a patient with impingement symptoms with forward ele-

vation or abduction, assistance for scapular elevation is provided by manually stabilizing the scapula and rotating the inferior border of the scapula as the arm moves. This procedure simulates the force-couple activity of the serratus anterior and lower trapezius muscles. Elimination or modification of the impingement symptoms indicates that these muscles should be a major focus in rehabilitation.

The scapular retraction test (Fig. 5) involves manually stabilizing the scapula in a retracted position on the thorax. This position confers a stable base of origin for the rotator cuff and often will improve tested rotator cuff strength. (That is, the apparent strength generated by isolated rotator cuff strength testing often improves by retesting in the scapula-retracted position.) The scapular retraction test also frequently demonstrates scapular and glenoid involvement in internal impingement lesions.<sup>26</sup> The positive posterior labral findings on modified Jobe relocation testing will be decreased with scapular retraction and removal of the glenoid from the excessively protracted impingement position.

Quantitative measurement of scapular stabilizer strength can be

achieved by the lateral scapular slide test.<sup>28</sup> This semidynamic test evaluates three positions of the scapula on injured and noninjured sides in relation to a fixed point on the spine as varying amounts of loads are put on the supporting musculature. These positions offer a graded challenge to the functioning of the shoulder muscles to stabilize the scapula. The first position is with the arms relaxed at the sides (Fig. 6, A). In this position, the inferior-medial angle of the scapula is palpated and marked on both the injured and noninjured sides. The reference point on the spine is the nearest spinous process, which is marked with an X. The measurements from the reference point on the spine to the medial border of the scapula are measured on both sides. The second position is with the hands on the hips, the fingers anterior and the thumb posterior with approximately 10° of shoulder extension. The new position of the inferomedial border of the scapula is marked, and the reference point on the spine is maintained. The distances once again are calculated on both sides. The same protocol is done for the third position, with the arms at or below 90° of arm elevation with maximal internal rotation at the glenohumeral



**Figure 6** Lateral scapular slide. **A**, Position 1: arms at rest at sides. **B**, Position 3: arms abducted at or below 90° with maximal internal rotation.

joint (Fig. 6, B). This final position presents a challenge to the muscles in the position of most common function at 90° of shoulder elevation. A 1.5-cm asymmetry is the threshold for abnormality and is most commonly seen in position 3. The lateral scapular slide test is more sensitive for dyskinetic patterns that occur with excessive protraction or other scapular movement away from the spine (types I and II).

Examination of other structures pertinent to the scapular evaluation includes assessment of arthrosis or instability of the acromioclavicular joint, shortening of the clavicle (from fracture or distal clavicle resection), and glenohumeral rotation and muscle strength.

### Treatment of Scapular Dyskinesis

Most of the abnormalities in scapular motion or position can be treated by physical therapy to relieve the symptoms associated with inflexibility or trigger points and to reestablish muscle strength and activation patterns.<sup>20,28,32</sup> Surgical treatment is used to repair the source of the underlying abnormalities and often is an integral part of the treatment program.

Bony abnormalities such as malunion of a clavicular fracture or an acromioclavicular joint separation may be the cause of the dyskinesia. More commonly, the source of muscle inhibition or imbalance is glenohumeral internal derangement, such as instability, labral tears, rotator cuff injury, or tendinitis. When structural problems or the internal derangement has been corrected, scapular muscle rehabilitation may be initiated.

### Rehabilitation

Once the complete and accurate diagnosis of all factors causing or contributing to scapular and shoulder

**Table 1**  
**Guidelines for Integrated Rehabilitation of Scapular Dyskinesis**

Exercises	Weeks (estimate)
<b>Scapular Motion</b>	
Thoracic posture	1-3
Trunk flexion/extension/rotation	1-3
Lower abdominal/hip extensor	1-5
<b>Muscular Flexibility</b>	
Massage	1, 2
Modalities (eg, ultrasound, electronic stimulation)	1-3
Stretching (eg, active-assisted, passive, PNF)	1-8
Corner stretches (pectoralis minor)	1-3
Towel roll stretches (pectoralis minor)	1-3
Levator scapulae stretches	1-3
"Sleeper" position stretches (shoulder external rotators)	1-3
<b>Closed Kinetic Chain Cocontraction Exercises</b>	
Weight-shifting	1, 2
Balance board	1, 2
Scapular clock	1, 2
Rhythmic ball stabilization	2
Weight-bearing isometric extension	1, 2
Wall push-up	2
Table push-up	3-5
Modified to prone push-up	5-8
<b>Axially Loaded AROM Exercise</b>	
Scaption slide	2-5
Flexion slide	2-5
Abduction glide	3-5
Diagonal slides	2-6
<b>Integrated Open Kinetic Chain Exercises</b>	
Scapular motion exercises plus arm elevation	3-8
Unilateral/bilateral tubing pulls with trunk motion	4-8
Modified lawn mower series	3-6
Dumbbell punches with stride (progressive height and resistance)	6-8
Lunge series with dumbbell reaches	5-8
<b>Plyometric Sport-Specific Exercises</b>	
Medicine ball toss and catch	6-10
Reciprocal tubing plyometrics	6-10

AROM = active range of motion, PNF = proprioceptive neuromuscular facilitation

der problems is established, scapular rehabilitation can be initiated.<sup>19,26,33</sup> Scapular rehabilitation is a component of comprehensive shoulder rehabilitation. Rehabilitation should start at the base of the kinetic chain,<sup>33</sup> which usually means correcting any strength or flexibility deficits in the low back and thoracic levels before starting on the scapular

component. This phase includes exercises for flexibility, strengthening the trunk, and correction of postural abnormalities.

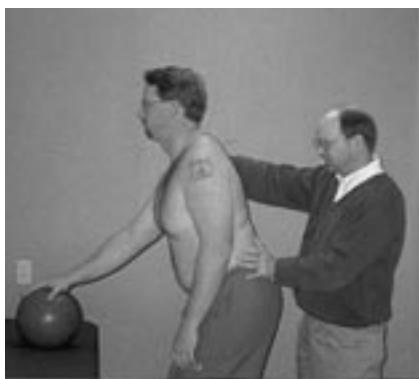Range of motion of the glenohumeral joint can be improved by appropriate stretching emphasizing the posterior capsule rather than stretching the entire upper limb. Scapular retraction and massage

can increase the tightness of the coracoid-based muscles.

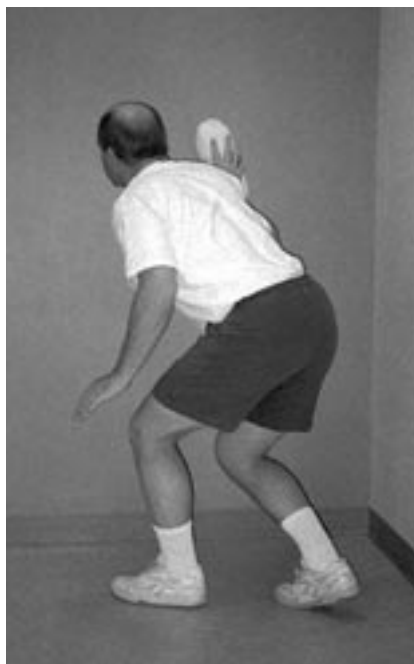### Rehabilitation Protocol

Rehabilitation of scapular dyskinesis (Table 1) is based on a proximal-to-distal protocol<sup>26,33</sup> (Figs. 7-10). It emphasizes achieving full and appropriate scapular motion and coordinating that motion with complementary trunk and hip movements. Once scapular motion is normalized, these movement patterns serve as the framework for exercises to strengthen the scapular musculature. Function, rather than time, determines a patient's progress through this protocol. In the early rehabilitation phases, hip and trunk motions are the foundation necessary to achieve appropriate scapular motion. As scapular control increases, scapular exercises may progress by decreasing the emphasis on proximal facilitation.

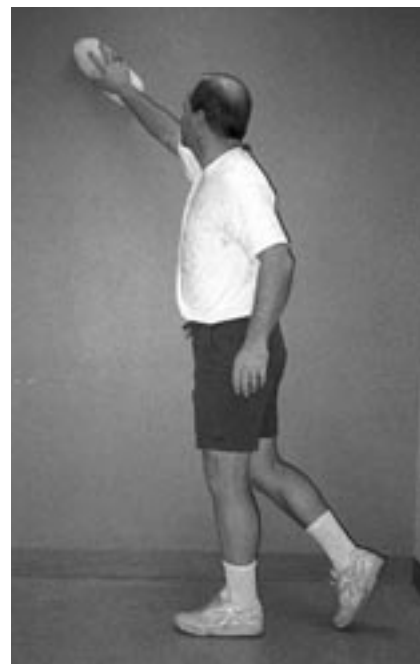
This protocol may be seen as a flow of exercises that progress as the patient achieves more proximal control and advances toward integration of the scapular exercises with shoulder and arm exercises. Outcome studies using this rehabilita-



**Figure 7** Closed-kinetic chain exercises. The body may be moved in relation to the fixed arm to determine a safe and non-painful plane of motion to start exercises. The arm may be placed on a ball to relieve excessive eccentric loads on the weak muscles.



**A**



**B**

**Figure 8** Wall slides. **A**, Starting position. **B**, Hip/trunk extension facilitating arm motion along smooth surface.

tion protocol have not been reported but are in progress. Our clinical experience has shown that achievement of scapular control decreases rotator cuff soreness and improves rotator cuff function, especially early in rehabilitation.

### Rehabilitation Phases

#### Acute Phase (Usually 0 to 3 Weeks)

(1) Initially, avoid painful arm movements and positions and establish scapular motion by proximal facilitation.

(2) Begin soft-tissue mobilization and assisted stretching if muscular inflexibility is limiting motion. Of particular importance are the pectoralis minor, levator scapulae, upper trapezius, latissimus dorsi, infraspinatus, and teres minor muscles. Active, active-assisted, passive, and proprioceptive neuromuscular facilitation stretching techniques are effective in restoring muscle flexibil-

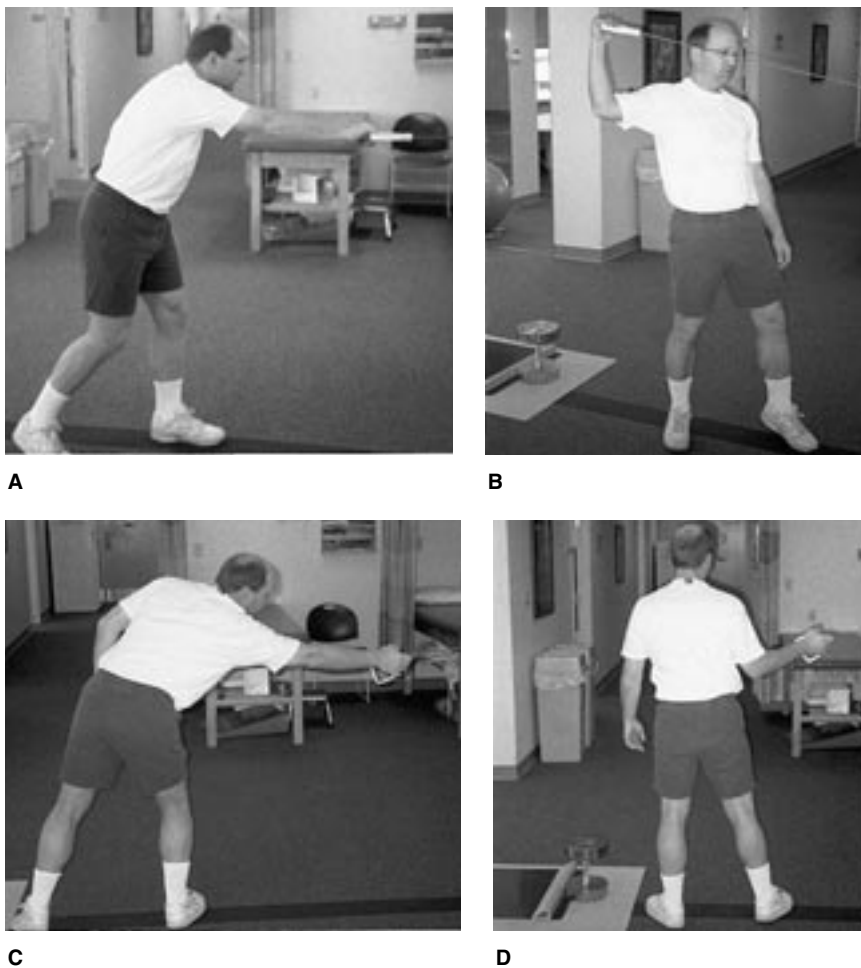
ity as well as the range of motion of glenohumeral joints.

(3) Begin upper extremity weight shifting, wobble board exercises, scapular clock exercises, rhythmic ball stabilization, and weight-bearing isometric extension to promote safe cocontractions. Use these closed kinetic chain exercises (CKC),<sup>34</sup> in which the hand is supported or has weight applied to it, in various planes and levels of elevation if the scapular positioning is appropriate. These may be started at low levels of abduction and external rotation, then may progress to 90° abduction as tolerated.

(4) Initiate scapular motion exercises without arm elevation. Use trunk flexion and trunk medial rotation to facilitate scapular protraction. Use active trunk extension, lateral trunk rotation, and hip extension to facilitate scapular retraction.

(5) Include arm motion with scapular motion exercises as the





**Figure 9** Kinetic chain tubing exercises, incorporating the trunk and scapula in various planes. **A**, Arm forward flexion. **B**, Ipsilateral hip/trunk extension with scapular retraction. **C**, Arm abduction. **D**, Contralateral hip/trunk extension with scapular retraction.

scapular motion improves. Initially, keep the arm close to the body to minimize the intrinsic load. An excellent early scapular stabilization exercise is the “low row,” which includes trunk/hip extension, scapular retraction, and arm extension.

*Recovery Phase (3 to 8 Weeks)*

Proximal stability and muscular activation are imperative for appropriate scapular motion and strengthening. Strengthening is dependent on motion, and motion is dependent on posture.

(1) Initiate greater loads with CKC exercises such as wall push-

ups, table push-ups, and modified prone push-ups. Also, increase the level of elevation of CKC exercises as scapular control improves. Position the patient for CKC exercises by placing the hand, then moving the body relative to the fixed hand to define the plane and degree of elevation (Fig. 7).

(2) Add arm elevation and rotation patterns to scapular motion exercises, as tolerated. If intrinsic loads are too great with the introduction of active elevation, use axially loaded active range-of-motion exercises as a transition to open kinetic chain exercises,<sup>34</sup> in which

the hand is freely movable. Wall slides are an example of transition exercises (Fig. 8).

(3) Begin kinetic chain tubing exercises using hip and trunk extension with scapular retraction, and hip and trunk flexion with scapular protraction (Fig. 9). Varying angles of pull and planes of motion are used to reproduce appropriate scapular functions.

(4) Use lunges with dumbbell reaches to emphasize kinetic chain timing and coordination. Vary the level of arm elevation, amount of external rotation, and degree of elbow flexion in the standing or return position to increase the functional demand on the scapular muscles. Avoid scapular compensations such as winging or shrugging.

*Maintenance Phase (6 to 10 Weeks)*

(1) When there is good scapular control and motion throughout the range of shoulder elevation, initiate plyometric (dynamic stretch-shortening) exercises, such as medicine ball toss and catch and tubing plyometrics.

(2) Overhead dumbbell presses and dumbbell punches (Fig. 10), in various planes are advanced exercises requiring good scapular control through a full and loaded glenohumeral range of motion.



**Figure 10** Dumbbell punches may be done in any safe plane.

## Summary

The scapula is coupled with the arm in normal shoulder function. Alterations in scapular motion and position are

frequently associated with shoulder injury and dysfunction. Recognition and evaluation of scapular dyskinesis can lead to a comprehensive framework for treating and rehabilitating the

entire shoulder joint. Rehabilitation exercises are structured in a proximal-to-distal protocol that advances toward integrating scapular exercises with shoulder and arm exercises.

## References

- Warner JJ, Micheli LJ, Arslanian LE, Kennedy J, Kennedy R: Scapulothoracic motion in normal shoulders and shoulders with glenohumeral instability and impingement syndrome: A study using Moire topographic analysis. *Clin Orthop* 1992;285:191-199.
- Doukas WC, Speer KP: Anatomy, pathophysiology, and biomechanics of shoulder instability. *Op Tech Sports Med* 2000;8:179-187.
- Poppen NK, Walker PS: Normal and abnormal motion of the shoulder. *J Bone Joint Surg Am* 1976;58:195-201.
- Pink MM, Perry J: Biomechanics of the shoulder, in Jobe FW, Pink MM, Glousman RE, Kvitne RS, Zemel NP (eds): *Operative Techniques in Upper Extremity Sports Injuries*. St. Louis, MO: Mosby-Year Book, 1996, pp 109-123.
- Niemenen H, Niemi J, Takala EP, Viikari-Juntura E: Load-sharing patterns in the shoulder during isometric flexion tasks. *J Biomech* 1995;28:555-566.
- McClure PW, Michener LA, Sennett BJ, Karduna AR: Direct 3-dimensional measurement of scapular kinematics during dynamic movements in vivo. *J Shoulder Elbow Surg* 2001;10:269-277.
- Happee R, Van der Helm FC: The control of shoulder muscles during goal directed movements: An inverse dynamic analysis. *J Biomech* 1995;28:1179-1191.
- Ludewig PM, Cook TM: Alterations in shoulder kinematics and associated muscle activity in people with symptoms of shoulder impingement. *Phys Ther* 2000;80:276-291.
- Lukasiewicz AC, McClure P, Michener L, Pratt N, Sennett B: Comparison of 3-dimensional scapular position and orientation between subjects with and without shoulder impingement. *J Orthop Sports Phys Ther* 1999;29:574-586.
- Fleisig GS, Barrentine SW, Escamilla RF, Andrews JR: Biomechanics of overhead throwing with implications for injuries. *Sports Med* 1996;21:421-437.
- McQuade KJ, Dawson J, Smidt GL: Scapulothoracic muscle fatigue associated with alterations in scapulothoracic rhythm kinematics during maximum resistive shoulder elevation. *J Orthop Sports Phys Ther* 1998;28:74-80.
- Kibler WB: Biomechanical analysis of the shoulder during tennis activities. *Clin Sports Med* 1995;14:79-85.
- Kennedy K: Rehabilitation of the unstable shoulder. *Op Tech Sports Med* 1993;1:311-324.
- Elliott BC, Marshall R, Noffal G: Contributions of upper limb segment rotations during the power serve in tennis. *J Appl Biomech* 1995;11:433-442.
- Kraemer WJ, Triplett NT, Fry AC: An in-depth sports medicine profile of women college tennis players. *J Sports Rehabil* 1995;4:79-88.
- Bagg SD, Forrest WJ: A biomechanical analysis of scapular rotation during arm abduction in the scapular plane. *Am J Phys Med Rehabil* 1988;67:238-245.
- Speer KP, Garrett WE Jr: Muscular control of motion and stability about the pectoral girdle, in Matsen FA III, Fu FH, Hawkins RJ (eds): *The Shoulder: A Balance of Mobility and Stability*. Rosemont, IL: American Academy of Orthopaedic Surgeons, 1993, pp 159-172.
- Bagg SD, Forrest WJ: Electromyographic study of the scapular rotators during arm abduction in the scapular plane. *Am J Phys Med* 1986;65:111-124.
- Moseley JB Jr, Jobe FW, Pink M, Perry J, Tibone J: EMG analysis of the scapular muscles during a shoulder rehabilitation program. *Am J Sports Med* 1992;20:128-134.
- Kuhn JE, Plancher KD, Hawkins RJ: Scapular winging. *J Am Acad Orthop Surg* 1995;3:319-325.
- Glousman R, Jobe F, Tibone J, Moynes D, Antonelli D, Perry J: Dynamic electromyographic analysis of the throwing shoulder with glenohumeral instability. *J Bone Joint Surg Am* 2000;22:220-226.
- Paletta GA Jr, Warner JJ, Warren RE, Deutsch A, Altchek DW: Shoulder kinematics with two-plane x-ray evaluation in patients with anterior instability or rotator cuff tearing. *J Shoulder Elbow Surg* 1997;6:516-527.
- Burkhart SS, Morgan CD, Kibler WB: Shoulder injuries in overhead athletes: The "dead arm" revisited. *Clin Sports Med* 2000;19:125-158.
- Harryman DT II, Sidles JA, Clark JM, McQuade KJ, Gibb TD, Matsen FA III: Translation of the humeral head on the glenoid with passive glenohumeral motion. *J Bone Joint Surg Am* 1990;72:1334-1343.
- Tyler TF, Nicholas SJ, Roy T, Gleim GW: Quantification of posterior capsule tightness and motion loss in patients with shoulder impingement. *Am J Sports Med* 2000;28:668-673.
- Kibler WB, McMullen J, Uhl T: Shoulder rehabilitation strategies, guidelines, and practices. *Op Tech Sports Med* 2000;8:258-267.
- Kibler WB, Uhl TL, Maddux JW, Brooks PV, Zeller B, McMullen J: Qualitative clinical evaluation of scapular dysfunction: A reliability study. *J Shoulder Elbow Surg* 2002;11:550-556.
- Kibler WB: The role of the scapula in athletic shoulder function. *Am J Sports Med* 1998;26:325-337.
- Young JL, Herring SA, Press JM, et al: The influence of the spine on the shoulder in the throwing athlete. *J Back Musculoskel Rehab* 1996;7:5-17.
- Weiser WM, Lee TQ, McMaster WC, McMahon PJ: Effects of simulated scapular protraction on anterior glenohumeral stability. *Am J Sports Med* 1999;27:801-805.
- Jobe FW, Kvitne RS, Giangarra CE: Shoulder pain in the overhead or throwing athlete: The relationship of anterior instability and rotator cuff impingement. *Orthop Rev* 1989;18:963-975.
- Kibler WB: Evaluation and diagnosis of scapulothoracic problems in the athlete. *Sports Medicine and Arthroscopic Review* 2000;8:192-202.
- McMullen J, Uhl TL: A kinetic chain approach for shoulder rehabilitation. *Journal of Athletic Training* 2000;35:329-337.
- Kibler WB, Livingston B: Closed-chain rehabilitation for upper and lower extremities. *J Am Acad Orthop Surg* 2001;9:412-421.