



DEVELOPMENTAL PHYSIOLOGY

Developmental kinesiology: Three levels of motor control in the assessment and treatment of the motor system



Alena Kobesova, MD, PhD*, Pavel Kolar, PedDr, PhD

Department of Rehabilitation and Sports Medicine, Second Medical Faculty, University Hospital Motol, Charles University, Prague, Czech Republic

Received 7 August 2012; received in revised form 11 March 2013; accepted 4 April 2013

KEYWORDS

Developmental kinesiology;
Sensorimotor control;
Primitive reflexes;
General movements;
Postural stabilization;
Developmental dyspraxia;
Dynamic neuromuscular stabilization

Summary Three levels of sensorimotor control within the central nervous system (CNS) can be distinguished. During the neonatal stage, general movements and primitive reflexes are controlled at the spinal and brain stem levels. Analysis of the newborn's spontaneous general movements and the assessment of primitive reflexes is crucial in the screening and early recognition of a risk for abnormal development. Following the newborn period, the subcortical level of the CNS motor control emerges and matures mainly during the first year of life. This allows for basic trunk stabilization, a prerequisite for any phasic movement and for the locomotor function of the extremities. At the subcortical level, orofacial muscles and afferent information are automatically integrated within postural–locomotor patterns. Finally, the cortical (the highest) level of motor control increasingly becomes activated. Cortical control is important for the individual qualities and characteristics of movement. It also allows for isolated segmental movement and relaxation. A child with impaired cortical motor control may be diagnosed with developmental dyspraxia or developmental coordination disorder. Human ontogenetic models, i.e., developmental motor patterns, can be used in both the diagnosis and treatment of locomotor system dysfunction.

© 2013 Elsevier Ltd. All rights reserved.

* Corresponding author. Department of Rehabilitation and Sports Medicine, University Hospital Motol, V Uvalu 84, 150 06 Prague 5, Czech Republic. Tel.: +420 22443 9264; fax: +420 22443 9220.
E-mail address: alenamudr@me.com (A. Kobesova).

The neonate

The neonate is functionally and anatomically immature (Fig. 1). Organized at the spinal and brainstem levels of the CNS control, primitive general movements (GMs) display characteristic quality and intensity, involving the entire body (Einspieler and Prechtl, 2005). The GMs (Prechtl, 1997; Hadders-Algra, 2004) are not triggered by any obvious external stimuli (Adde et al., 2007) and do not serve any specific purpose, such as grasping, reaching or support. For example, a newborn cannot grasp purposefully; grasping reflex is an automatic, involuntary response to proprioceptive and tactile palm stimulation and does not serve a purposeful grasp. The absence of antagonistic co-activation, which is typical for early postural behavior, does not allow for segmental stability. Therefore, postural adjustment is quite different from the later development when motor functions such as reaching or walking occur (Hadders-Algra, 2005). Purposeful reaching also requires coordinated activity of the head, eyes and hand which, in turn, depends on trunk support. Such coordination is not available in the neonatal stage and appears only at 4 months of age (Bertenthal and Von Hofsten, 1998). A newborn's ability to hold a segment in a static position against gravity is very limited (Bertenthal and Von Hofsten, 1998; Orth, 2005). The body follows head rotation and an asymmetrical posture occurs (Orth, 2005). According to Prechtl, newborns are able to balance their head for a few seconds in a sitting position (Prechtl, 1997). Although ocular-motor coordination starts from the first month of life (Bloch and Carchon, 1992), constant visual fixation and tracking are quite limited in a newborn. This ability appears at 1 month of age and rapidly increases over the next few months of life. The contribution of head movements to visual tracking also appears at 1 month of age (Bertenthal and Von Hofsten, 1998). Orofacial muscle activity, including the tongue, becomes organized within general movements. Healthy newborn can coordinate sucking, swallowing and breathing which allows for a normal sucking pattern (Palmer et al., 1993).

Assessment of neonatal motor behavior can serve as a very early pediatric screening tool (Adde et al., 2007; Burger and Louw, 2009). The normal physiology of newborn

GMs consists of a series of gross movements of variable speed and amplitude that involve all parts of the body (Hadders-Algra, 2004). For example, a newborn typically keeps its fists closed with the thumb inside the palm (Fig. 1). However, as a general movement of the arm occurs, it also involves the hand, leading to hand opening and the thumb moving outside the fist (Fig. 2). Under normal physiological conditions, the fist is not a fixed postural pattern (Hadders-Algra, 2004; Orth, 2005; Vojta, 2008). In the neonatal period, the GMs are writhing, "elegant", rather slow with specific amplitude and involve not only the extremities, but also the trunk and orofacial muscle systems. For example, under pathological conditions in infants who later develop cerebral palsy (CP), not only that their posture is different (Fig. 1C), but also their global movement patterns demonstrate different quality, which is best described as "cramped-synchronized" rather than "elegant". They involve mainly the proximal segments and muscles, with different intensity, speed and amplitude (Prechtl et al., 1997; Adde et al., 2007). Abnormal GMs are insufficiently variable and lack complexity and fluency (Hadders-Algra, 2004). Posturally, the physiologically normal neonate may prefer head rotation towards one side, which is known as "predilection" (Fig. 1A) (Orth, 2005; Vojta, 2008). However, the head rotation is not fixed and, even during the newborn stage, every healthy newborn should be able to rotate the head across midline.

Primitive & postural reflexes

During the neonatal stage, primitive reflexes organized at the spinal and brain stem levels can be elicited. Utilizing adequate proprioceptive and exteroceptive (non nociceptive) stimulation, certain reflexes, such as the crossed extensor reflex, suprapubic reflex, step reflex, supporting reflex and other reflexes (Fig. 3), can be observed. The assessment of spontaneous complex motor behavior, primitive reflexes and seven postural tests as outlined by Vojta can be used to examine the infant's developmental age. They can be used to determine whether the development is physiologically normal or whether there is a risk for an abnormal development (Zafeiriou, 2004; Orth, 2005; Vojta, 2008). An experienced clinician may even predict the

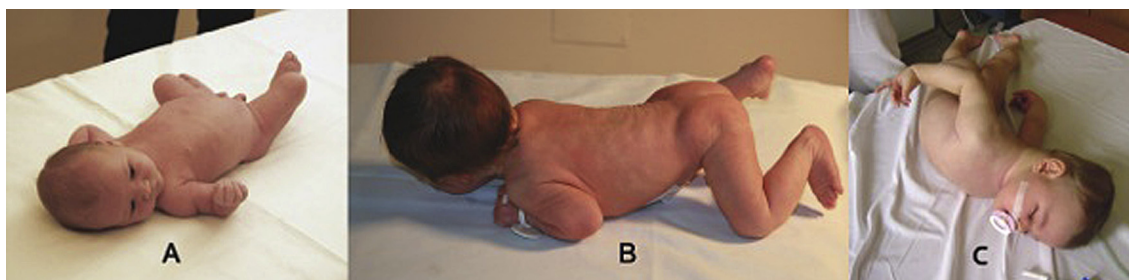

Figure 1 Neonate. A: A typical supine posture with the head rotated toward one side (called predilection), the hand closed in fist with thumb inside the palm, cranial chest position, no postural activity in abdominal muscles. B: A typical prone posture: the chest is the weight bearing area, the arm is in adduction, fist with thumb inside the palm, scapular elevation, anterior pelvic tilt, the baby cannot hold the head steadily above the mat as a result of a lack of equilibrium and a lack of supporting arm function. C: Baby with cerebral palsy – a pathological posture with opisthotonus; both the posture and quality of movements are different in comparison with those found in an optimally developing baby.

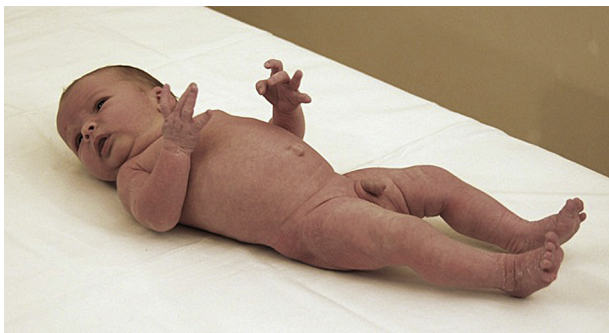

Figure 2 Within general movements, the thumb moves outside the palm.

severity of impairments and the type of CP likely to develop in a particular infant. These quick, noninvasive and inexpensive assessments should be performed during the neonatal stage. This would allow for the initiation of an early treatment where necessary, before any pathological stereotypes become fixed leading to a subsequent morphological damage. Primitive reflexes organized on spinal and brain stem levels do not “disappear” after the neonatal stage. These motor patterns are simply inhibited by higher levels of control as the CNS matures. They become integrated within more complex patterns controlled at the subcortical and cortical levels. Under pathological conditions, such as brain injury or stroke, the

primitive reflexes or its components become disinhibited and reappear, sometimes being described by a neurologist as positive pyramidal signs.

Musculoskeletal development

Functional neonatal immaturity goes hand in hand with anatomic immaturity. Spinal curves are not yet defined (Abitbol, 1987; Lord et al., 1995; Kasai et al., 1996), the chest is barrel shaped (the anteroposterior diameter is longer than the width; unlike in the adulthood), the tibial plateau is oblique, the arch of the foot is not yet formed (Forriol Campos et al., 1990; Volpon, 1994), etc. Anatomic maturation continues after birth and, besides other factors (i.e. genetic, hormonal, metabolic, and immunological), it depends on the CNS control of muscle function. Muscles pulling on the epiphyseal plates greatly influence structural formation. Therefore, it is critical that the muscles acting on the epiphyseal plates function in balance. Correct CNS control ensures proportional activation between the adductors and abductors, external and internal rotators, flexors and extensors and allows for an ideal skeletal formation. In a child with CP, both an abnormal motor and sensory function and the occurrence of anatomical deformities resulting from an abnormal CNS control can be observed (Volpon, 1994; DeLuca, 1996; Koman et al., 2004; Davids, 2010). To a certain extent, this may be positively influenced by initiating an early and targeted treatment

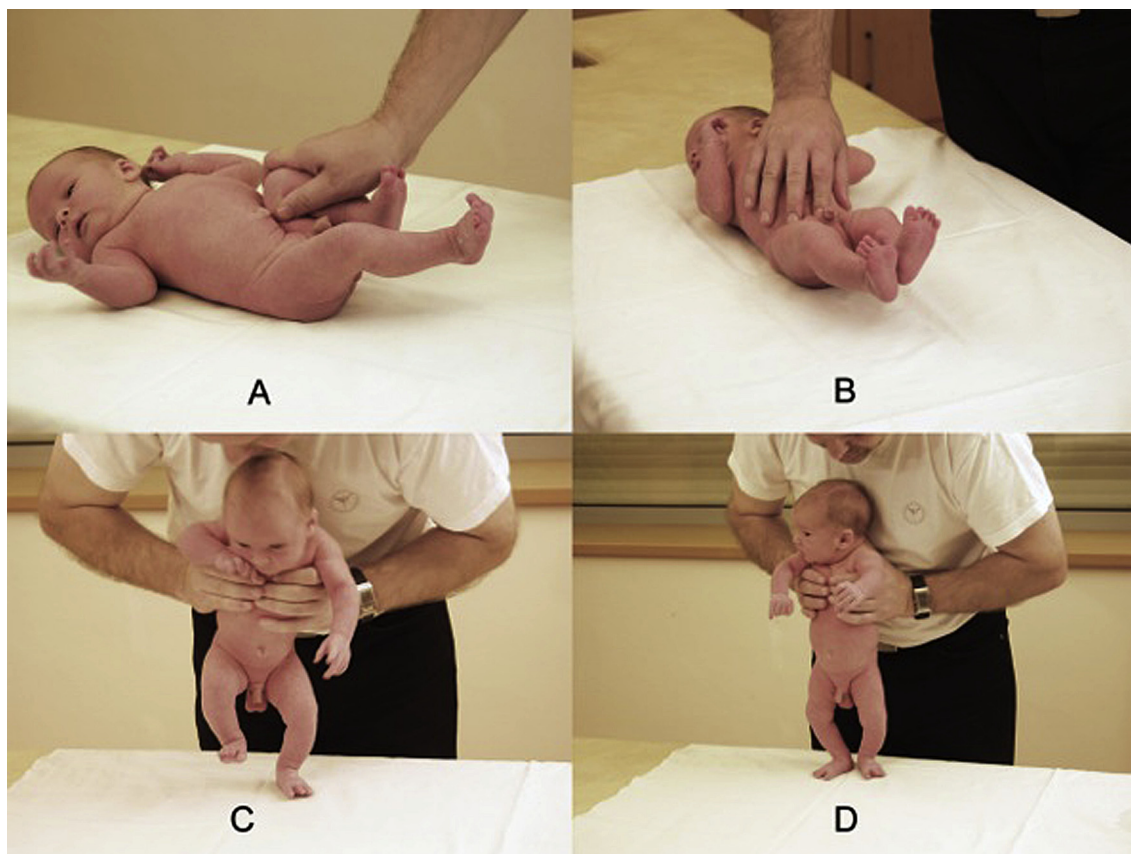


Figure 3 Primitive reflexes: A – crossed extensor reflex, B – suprapubic reflex, C – step reflex, D – supporting reflex.

(Morrell et al., 2002; Hägglund et al., 2005; Picciolini et al., 2009).

The evaluation of spontaneous motor behavior, primitive reflexes and postural reactions as a functional clinical assessment can also serve as an important clinical tool to re-evaluate the infant and to assess the effect of the implemented therapy. It serves as a feedback to both the clinician and the parent, but may also allow for comparison of different types of treatment strategies (Vojta, 1972a, 1972b; Morrell et al., 2002). The concepts of Bobath and Vojta (Bobath, 1980; Bobath and Bobath, 1984; Vojta, 2008; Vojta and Schweizer, 2009) are the two most common therapeutic approaches utilized in newborns and toddlers with abnormal development.

The infant

When the neonatal developmental period is completed (the first 28 days after birth), the postural–locomotor function related to maturation of the subcortical CNS (second) level of motor control begins. Prior to movement of an extremity, the head or the neck, the core needs to brace within the gravitational field (Hodges, 2004). To stabilize the neck and the upper thoracic spine, balanced synergy between the neck flexors and spinal extensors is required (Kapandji, 1992). A feed-forward activation of both the neck flexors and extensors is a necessary mechanism for stability of limb movements as well as for the visual and vestibular systems; therefore ensuring stabilization and protection of the cervical spine (Falla et al., 2004). To stabilize the lower thoracic and lumbar spine, a complex synergy between the diaphragm, pelvic floor, abdominal wall and spinal extensors is essential. Harmonious concentric activity of the diaphragm and the pelvic floor is followed by eccentric activity of all sections of the abdominal wall. This muscle synergy increases intra-abdominal pressure, thereby stabilizing the low back from the front. Under ideal conditions, this activity is in balance with the spinal extensors (Fig. 4) (Cholewicki et al., 1999; Hodges and Gandevia, 2000; Essendrop et al., 2002; Hodges et al., 2005, 2007; Kolar et al., 2009).

This stabilizing muscle synergy develops during the first 4.5 months of life. After the neonatal period, the infant begins to lift their legs in supine (Fig. 5A) and lift their head when prone (Fig. 5B). For postural activity to occur, balance among all the stabilizers is necessary and depends on optimal utilization of the supporting segments. A 3-month old infant can lift their legs and weightbear on the upper sections of the gluteal muscles while maintaining an upright spine (Adde et al., 2007; Vojta, 2008). The chest and pelvis are in a neutral position, the axis of the chest and pelvis are in a parallel alignment, thus allowing for a balanced postural function.

In a newborn, the diaphragm fulfills mainly its respiratory function (Murphy and Woodrum, 1998). It starts to act as an important stabilizer (Kolar et al., 2009; Vojta and Schweizer, 2009) after the neonatal period. While prone, the baby utilizes the medial epicondyles of the elbows and the pubic symphysis as support zones (Fig. 5B). The same stabilizing muscle synergy occurs in supine (Fig. 5A) and allows the baby to lift the legs with the spine perfectly

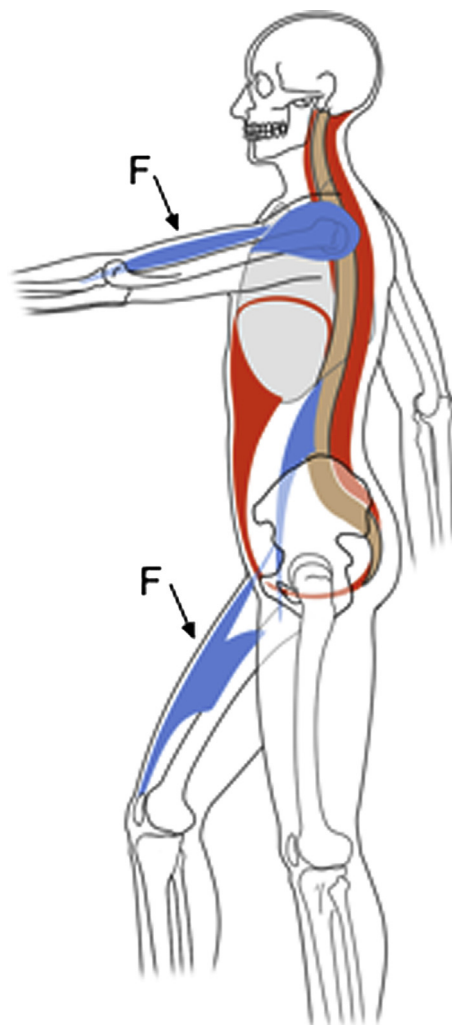


Figure 4 Schematic illustration of muscles stabilizing the shoulder and pelvic girdle and the spine. Under a physiological condition, the stabilizers: in red – the diaphragm, the pelvic floor, all the sections of the abdominal wall and the spinal extensors – automatically activate prior to purposeful movement (e.g. hip flexion provided by the muscles in blue: the iliopsoas, rectus femoris, sartorius) to establish a stable base (“Feed forward mechanism”). In healthy subjects, the stabilizing function of the trunk (in red) muscles prevents malalignment of the lumbar segments during hip flexion. Well balanced activity between the deep neck flexors and the spinal extensors is necessary for stabilization in the cervical and upper thoracic regions. (For interpretation of the references to colour in this figure legend, the reader is referred to the web version of this article.)

upright (Hermesen-van Wanrooy, 2006; Vojta and Schweizer, 2009). Since the upper thoracic segments functionally belong to the cervical spine, as the infant lifts their head, the movement is initiated in T3/4/5 segments at the origin of the neck extensors: semispinalis cervicis and capitis, splenius cervicis and capitis. The extensors work in balance with the deep neck flexors (Kapandji, 1992). It is important for the activity of all the stabilizers to be proportional. If one link (a muscle or just a certain section of a muscle) is weak, it must be counterbalanced by another muscle,




Figure 5 A 3-month old baby, supine and prone: a model of optimal trunk sagittal stabilization.

leading to an imbalance in the global stabilization chain (Lewit, 2010). Unless restored early by therapy, it may remain for the rest of life and become a primary etiological factor in the development of chronic pain in the locomotor system (Kolar et al., 2010, 2011).

Emotional motivation is also an important component in postural development. The infant starts to lift their head and legs to adjust the entire posture to be able to look around, later to grasp and, eventually, to start moving. Proper interaction with the environment influences the infant's complex behavioral repertoire (Bell et al., 2008).

Differentiation of extremity movement

After basic stabilization of the core in the sagittal plane is completed, the locomotor function of extremities occurs (Hermesen-van Wanrooy, 2006; Vojta and Schweizer, 2009). At 4.5 months, the infant starts to reach across the midline when supine. Motivation, once again, triggers trunk rotation at the age of 5 months when the infant can turn to a sidelying position (Fig. 6) and complete rolling from supine to prone at 6 months of age.

The ipsilateral pattern of extremity locomotor function develops from the supine position. The ipsilateral (bottom

when sidelying: Fig. 6) extremities serve as support. These are activated in a closed kinetic chain, the direction of muscle pull is distal and the proximal segments (e.g. the acetabulum at the hip and/or the glenoid cavity at the shoulder) move against the fixed head of the femur and the humerus. Reciprocal, or the stepping forward and grasping/reaching function, occurs in the opposite (top) extremities. They are activated in an open kinetic chain, where the direction of muscle pull is proximal, the distal part of the segment moves against the fixed proximal part, i.e. the humeral and femoral head move against a fixed glenoid cavity or the acetabulum, respectively.

In the prone position, the contralateral pattern of locomotor function develops (Fig. 7). If the left arm serves as a support, the infant simultaneously weightbears on the right knee, with the right arm reaching and the left leg stepping forward. The kinetic chain principles are the same as described for the ipsilateral pattern. Stepping forward and supporting functions are reciprocal; they are the same movements, only in opposite directions.

Both supporting and stepping forward extremity functions fully depend on trunk stabilization (Hodges, 2004). Therefore, during development, stabilization must initially occur in the spine, chest and pelvis and only then it is

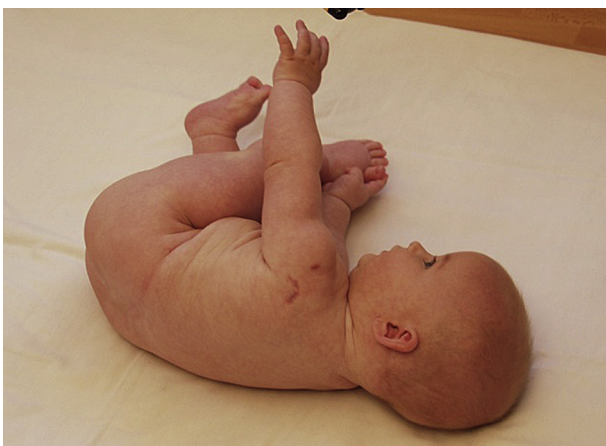

Figure 6 6 month old baby, side lying position – ipsilateral pattern of locomotion extremity function based on optimal core stabilization: bottom extremities serve for support, top extremities are stepping forward/reaching.



Figure 7 Contralateral postural-locomotion pattern: right leg, left arm: supporting; left leg, right arm: stepping forward (reaching).

followed by a phasic extremity function. The same is true for a spontaneous motor behavior for the rest of life.

Joint centration and stabilization

Prior to any movement, the core needs to brace (Hodges, 2004; McGill et al., 2009; Borghuis et al., 2008). Naturally, conscious focus is on the phasic part of any movement, while the stabilizing function is subconscious and automatic. Therefore, stability is often compromised and not easily re-trained. It is suggested that corrective stabilization training should be a primary step in any rehabilitation program (Akuthota et al., 2008; Kobesova et al., 2012; Frank et al., 2013). Balance or strengthening exercises prescribed to a patient with poor stabilization will have limited effect or they may even promote pathological patterns of movement and exacerbate the patient's pain (Akuthota et al., 2008; Kolář and Kobesová, 2010; Kolar et al., 2011).

Assuming that core stability and basic extremity locomotor function are mainly under the subcortical CNS control, if CNS control is adequate, and muscles are activated in balance, then each posture and each spontaneous movement automatically bring all the joints into a functionally centred position. The functionally centred (neutral or functionally optimal) joint is not a static position but a dynamic neuromuscular strategy that leads to the most optimal joint position which then facilitates the most effective mechanical advantage throughout the entire range of motion. The joint contact area between the joint head and the cavity is affected by ligament strain (Novotny et al., 2000), and it is assumed that the centred joint has the greatest interosseous contact, which allows for optimal load transfer across the joint and throughout the kinetic chain. This implies maximum loading, minimum tension in the joint capsule and the ligaments, and the protection of all joint structures during loading.

It should be noted that postural–locomotor function also involves orofacial muscles and is greatly influenced by all afferent stimuli. The CNS constantly processes all tactile, proprioceptive, visual, vestibular and acoustic stimuli. This can be demonstrated by visual integration (Fisk and Goodale, 1985; Gribble et al., 2002; Henriques et al., 2003). During development, the physiologically normal infant is curious and desires to explore the environment. To be able to observe their surroundings, the infant adopts the most suitable posture, activates support function in order to stabilize the entire body within gravity and then looks around. Thus, the baby lifts the legs in supine or lifts the head in prone while the eyes lead during the stepping forward function. At the age of 5–6 months, the infant turns the eyes towards an object of interest, which triggers arm reaching followed by rolling. This synergy remains for the rest of life. A tennis player turns his eyes in the direction of the ball as he prepares to hit it while his tongue moves in the same direction (Fig. 8). Here, the movement of the eyes and the tongue facilitates a postural–locomotor pattern, which promotes and enhances sport performance.

The scenario of a grasping reflex versus an active grasp serves as another example. If the newborn's palm is touched, the baby automatically grasps (Orth, 2005; Vojta,



Figure 8 A tennis player – integration of eyes, tongue and orofacial muscles within the postural–locomotor pattern.

2008). This is a reflex organized at the spinal and brain stem level. Since the stereognosis has yet not matured in the palm of a newborn, the infant does not feel the hand contact. The grasp is automatic, involuntary and does not serve as an active grip. Later, between the 3rd and 4th month of life, stereognosis in the palm develops and, at the same time, the infant starts to grasp actively and purposefully. Sensory perception is a prerequisite for motor function (Metcalfe et al., 2005). These principles can be effectively utilized in rehabilitation treatment to achieve optimum stabilization and movement performance.

Various rehabilitation approaches can be used to assess and restore an ideal muscle synergy to stabilize the core. Dynamic Neuromuscular Stabilization (DNS) concept (Kolář and Kobesová, 2010; Frank et al., 2013) may serve such a purpose. DNS assessment is based on comparing the patient's stabilization pattern with the stabilization patterns typical for physiological development. A healthy infant automatically utilizes ideal muscular synergy to stabilize their spine, pelvis and chest in various positions. DNS is based on the developmental positions and describes a set of functional tests to assess the quality of patient's stabilization and to recognize a key link in dysfunction. The treatment is based on developmental positions (see Fig. 9). The goal is to achieve optimal muscle coordination by placing the patient into various developmental positions while bringing the supporting joints and segments into a functionally centred position. At first, the patient is manually and verbally guided to recognize the difference between the poor and the optimal stabilizing stereotype. Then, the patient is instructed to maintain the optimal pattern in different positions and later also during a movement. Since the stereotype of stabilization is closely related to a respiratory pattern (Kolar et al., 2009, 2010, 2011), the DNS assessment always includes the evaluation of a breathing pattern. The training also addresses simultaneous stabilizing and respiratory functions. The ultimate goal of DNS is to teach the patient the integration of an optimal pattern of breathing and stabilization within the activities of daily living and sport performance.



Figure 9 Examples of exercise in developmental positions. Through verbal and manual guidance the patient is instructed to achieve the same quality of postural—locomotion function. A: An oblique sitting position corresponding with developmental posture at 8 months of age. B: A crawling position corresponding with developmental posture at 10 months of age. C: A “high kneeling” position corresponding with developmental posture at 10–11 months of age. D: A squat position corresponding with developmental posture at 12 months of age.

Cortical function

The cortical level of motor integration presents the highest level of CNS control. It incorporates gnostic function, such as multisensory integration, allowing for body image, self-location and first-person perspective (Ionta et al., 2011). The better the body perception, the better the quality of phasic movement, the better the ability to perform isolated movement in only one segment and the better the ability to relax.

Even with the eyes closed, it should be possible to “read” one’s own body (Mon-Williams et al., 1999). We know if we are sitting or standing, if our elbow is flexed or extended, if we wear short or long sleeves, if our posture is static or dynamic, etc. With our eyes closed, we should be able to demonstrate our body proportions. For example, we should be able to quite precisely draw the size of the foot, demonstrate the width of the pelvis (Fig. 10), or the size of the mouth. Body perception, primarily proprioception, allows differentiation of an object’s weight, position and motion. We can “read” a joint position (Mon-Williams et al., 1999) and repeatedly perform the same movement. These principles are critical in both sport performance and rehabilitation. The better the body image the more precise and efficient the movement is. Clumsiness

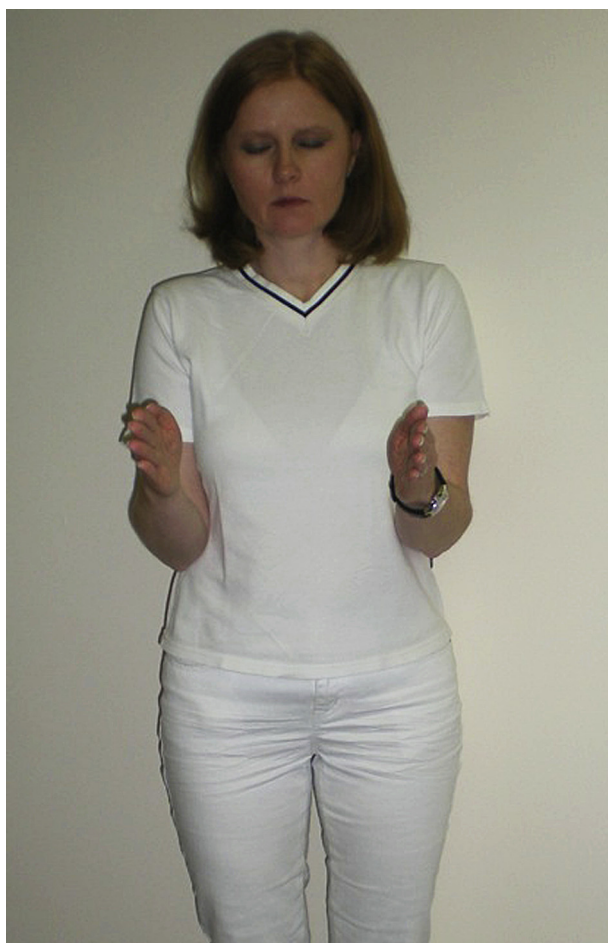

Figure 10 The body perception test: using the hands, the person demonstrates the width of their pelvis.

and poor coordination may be related to abnormal proprioceptive control (Adib et al., 2005).

Visual perception is also essential for purposeful movement (Mon-Williams et al., 1999). It allows for estimation of distance and speed as well as facilitation of an adequate and coordinated motor response within our surroundings. For example, the earlier a tennis player sees an approaching ball, the quicker the estimate of the angle, direction, and speed of the ball. Continuing the tennis example, an individual’s quality of visual perception would be a key aspect to success (Moreno et al., 2005; Ghasemi et al., 2011). Visual perception and integration at a cortical level enables us to mimic body positions, movements, or gestures of another person—a critical aspect in sport and rehabilitation.

Vestibular perception is important not only for postural balance (Angelaki and Cullen, 2008), but also for vertical line perception. The perception of visual vertical is altered in individuals with idiopathic scoliosis (Čakrt et al., 2011) and may play a role in the development of scoliosis. Whether an individual with idiopathic scoliosis perceives vertical line differently because of the scoliosis, or if the scoliosis is in fact a consequence of abnormal vertical line perception, is a topic open to discussion.

Even skin perception influences our motion (Edin and Johansson, 1995). Skin input contributes to both dynamic position and velocity sense (Cordo et al., 2001). Very often, the perceptiveness at the segment is restored after manipulation or mobilization, which in turn allows for a longer lasting effect of the manual technique applied.

Altered multi-sensory CNS integration may result in poor motor planning, poor motor re-education (Polatajko and Cantin, 2005), or a difficulty performing the simplest task. Such individuals cannot adjust their muscle strength to the actual demand, and usually activate too many unnecessary muscles for stabilization, making the movements inefficient. They demonstrate poor diadochokinesis as well as poor fluency and speed adjustment. A person with altered sensory integration can barely perform selective movements in only one joint, and usually have great difficulty relaxing postural muscles.

Research shows that insufficient uni- or multi-sensory integration at the cortical level may lead to painful syndromes within the locomotor system (Flor et al., 1997; Imamura et al., 2009). Injuries, degenerative joint disorders, enthesopathies, orthopedic problems resulting from chronic overload and repetitive stress injuries are typical consequences. These disorders are usually considered to be primary diagnoses rather than a consequence of an altered sensorimotor integration and CNS control which is more likely to be the real etiology. The therapy then only targets “the diagnosis” rather than the primary etiology. Consequently, the chosen therapy usually ends up being unsuccessful in the long run.

In patients with poor integration of afferent information (i.e. where poor body image is a key problem), it is advised to integrate body perception training within the rehabilitation program. The patient may be taught to focus on a particular body part with compromised sensory perception. First, with the eyes closed, the patient may be instructed to realize the initial position in a segment, then to slowly move the segment while focusing on

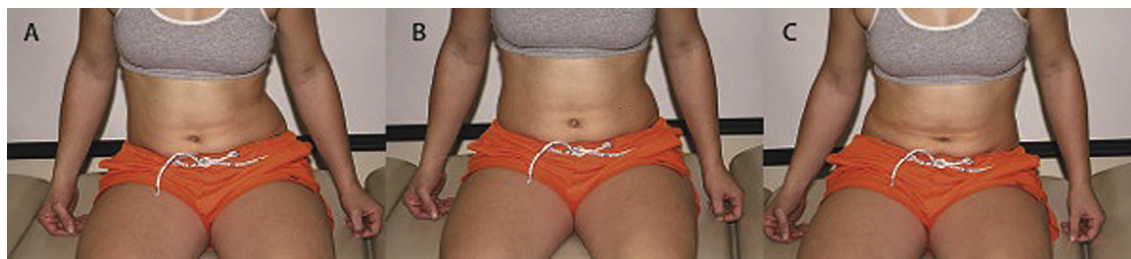

Figure 11 An example of body image training in the area of pelvis: The patient is instructed to imagine sitting on a clock and to slowly move the pelvis around the clock (the range of movement is rather small) while fully focusing on the precise selective pelvic movement and maintaining proper course stability as well as avoiding any pathological synkinesis (e.g. lumbar spine extension and flexion within pelvic rotation).

movement in this segment only. The rest of the body should be relaxed. The patient is instructed to train isolated movement in one particular segment while fully realizing the course of the movement, its direction and range. Any pathological synkinesis or any substitutive patterns need to be avoided. The patient should also learn how to isolate a movement in one segment only and how to switch between muscle activation and relaxation. The patient learns how to “read their own body” without visual control (see Fig. 11). Feldenkrais concepts can also be utilized to train cortical control of movement accuracy and body image (Feldenkrais, 1999).

Developmental dyspraxia or developmental coordination disorder

In childhood, insufficient uni- or multi-sensory integration is usually diagnosed as developmental dyspraxia or developmental coordination disorder (DCD) (Polatajko and Cantin, 2005; Gibbs et al., 2007; Kirby and Sugden, 2007). The Movement Assessment Battery for Children (MABC) (Henderson et al., 2007) and Bruininks–Oseretsky Test of Motor Proficiency (BOTMP) (Wilson et al., 1995) can be used to diagnose developmental dyspraxia. Children with DCD who are involved in sports often complain of nonspecific symptoms such as exhaustion, acute headache, vertigo and nausea, especially during increased athletic activity (Gibbs et al., 2007; Henderson et al., 2007). Such complaints are usually considered vertebrogenic or psychosomatic. The symptoms of DCD are to a certain extent resistant to conventional treatment. An appropriate therapy should be introduced as soon as the diagnosis is established (Hung and Pang, 2010). Sport activities should be integrated within the treatment strategy and team sports are especially recommended. The therapeutic procedures should become a routine part of activities of daily living (ADL) (Schott et al., 2007; Poulsen et al., 2008).

Cerebellar function

The cerebellum is involved in all three levels of integration and matures simultaneously with other parts of the brain. This plays an important role in muscle tone regulation, postural and balance maintenance. It helps to regulate the movement’s accuracy, including very precise movements, such as playing musical instruments (Beaton and Mariën,

2010). The cerebellum coordinates movements in time and space and plays an important role in cognition (Beaton and Mariën, 2010) and speech (De Smet et al., 2007). It develops during ontogenesis. At 3 months of age, the functional activity in the cerebellum increases substantially (Chugani, 1998; Hadders-Algra, 2005) and its maturation continues along with the rest of the brain until adulthood. According to Hadders-Algra, the nervous system obtains its adult configuration at approximately 30 years of age. Based on the available research (Grossberg and Paine, 2000; Katanoda et al., 2001), we assume that it is especially the maturation of the cerebellar cortex and frontal and parietal cortices that allows for hand motor dexterity that is sufficient for writing at the age of 6, the age that, in most countries, correlates with the beginning of school education which is the age at which hand movement accuracy allows for writing. Also, at that age, language and cognitive functions are sufficiently developed. All three aspects play a critical role in school education as well as in rehabilitation.

Conclusion

General neurophysiological principles are presented, which may be utilized in both the functional diagnosis and the treatment of locomotor system dysfunctions, as well as in many other cases involving neurologic and/or orthopaedic diagnoses. Motor stereotypes are seen to be organized at different levels of the CNS which may be potentially useful in both clinical assessment and treatment. A set of dynamic movement tests may be used to identify important dysfunctional features in a compromised postural-locomotor pattern. Postural exercises based on ideal ontogenetic patterns may be used to achieve optimal postural function and phasic movements. It is suggested that these methods should not be conceived as comprising a treatment technique, but rather an educational approach based on neurophysiology of individuals with chronic musculoskeletal pain.

Acknowledgements

We would like to thank Ida Nørgaard, DC MSc for invaluable help in preparing this manuscript. This study was supported by Rehabilitation Prague School, by the foundation

Movement without Help, Prague, Czech Republic, and by the Grant PRVOUK 38.

References

- Abitbol, M.M., 1987. Evolution of the lumbosacral angle. *Am. J. Phys. Anthropol.* 72, 361–372.
- Adde, L., Rygg, M., Lossius, K., Oberg, G.K., Støen, R., 2007. General movement assessment: predicting cerebral palsy in clinical practise. *Early Hum. Dev.* 83, 13–18.
- Adib, N., Davies, K., Grahame, R., Woo, P., Murray, K.J., 2005. Joint hypermobility syndrome in childhood. A not so benign multisystem disorder? *Rheumatol. (Oxford)* 44, 744–750.
- Akuthota, V., Ferreiro, A., Moore, T., Fredericson, M., 2008. Core stability exercise principles. *Curr. Sports Med. Rep.* 7, 39–44. <http://dx.doi.org/10.1097/01.CSMR.0000308663.13278.69>.
- Angelaki, D.E., Cullen, K.E., 2008. Vestibular system: the many facets of a multimodal sense. *Annu. Rev. Neurosci.* 31, 125–150.
- Beaton, A., Mariën, P., 2010. Language, cognition and the cerebellum: grappling with an enigma. *Cortex* 46, 811–820. <http://dx.doi.org/10.1016/j.cortex.2010.02.005>.
- Bell, A.F., Lucas, R., White-Traut, R.C., 2008. Concept clarification of neonatal neurobehavioural organization. *J. Adv. Nurs.* 61, 570–581. <http://dx.doi.org/10.1111/j.1365-2648.2007.04561.x>.
- Bertenthal, B., Von Hofsten, C., 1998. Eye, head and trunk control: the foundation for manual development. *Neurosci. Biobehav.* 22, 515–520.
- Bloch, H., Carchon, I., 1992. On the onset of eye–head coordination in infants. *Behav. Brain Res.* 49, 85–90.
- Bobath, K., 1980. *A Neurophysiological Basis for the Treatment of Cerebral Palsy*. Mac Keith Press, Lavenham.
- Bobath, K., Bobath, B., 1984. The neurodevelopmental treatment concept. In: *Scrutton, D. (Ed.), Management of the Motor Disorders of Children With CP. Clinics in Developmental Medicine*, vol. 90, pp. 7–12.
- Borghuis, J., Hof, A.L., Lemmink, K.A., 2008. The importance of sensory-motor control in providing core stability: implications for measurement and training. *Sports Med.* 37, 893–916.
- Burger, M., Louw, Q.A., Sep 2009. The predictive validity of general movements—a systematic review. *Eur. J. Paediatr. Neurol.* 13, 408–420.
- Čákr, O., Slabý, K., Viktorinová, L., Kolář, P., Jeřábek, J., 2011. Subjective visual vertical in patients with idiopathic scoliosis. *J. Vestib. Res.* 21, 161–165.
- Cholewicki, J., Juluru, K., Radebold, A., Panjabi, M.M., McGill, S.M., 1999. Lumbar spine stability can be augmented with an abdominal belt and/or increased intra-abdominal pressure. *Eur. Spine J.* 8, 388–395.
- Chugani, H.T., 1998. A critical period of brain development: studies of cerebral glucose utilization with PET. *Prev. Med.* 27, 184–188.
- Cordo, P.J., Horn, J.L., Künster, D., Cherry, A., Bratt, A., Gurfinkel, V., 2001. Contributions of skin and muscle afferent input to movement sense in the human hand. *J. Neurophysiol.* 105, 1879–1888. <http://dx.doi.org/10.1152/jn.00201.2010>.
- Davids, J.R., 2010. The foot and ankle in cerebral palsy. *Orthop. Clin. North. Am.* 41, 579–593.
- De Smet, H.J., Baillieux, H., De Deyn, P.P., Mariën, P., Paquier, P., 2007. The cerebellum and language: the story so far. *Folia Phoniatr. Logop.* 59, 165–170.
- DeLuca, P.A., 1996. The musculoskeletal management of children with cerebral palsy. *Pediatr. Clin. North. Am.* 43, 1135–1150.
- Edin, B.B., Johansson, N., 1995. Skin strain patterns provide kinesthetic information to the human central nervous system. *J. Physiol.* 487 (Pt1), 243–251.
- Einspieler, C., Prechtl, H.F., 2005. Prechtl's assessment of general movements: a diagnostic tool for the functional assessment of the young nervous system. *Ment. Retard. Dev. Disabil. Res. Rev.* 11, 61–67.
- Essendrop, M., Andersen, T.B., Schibye, B., 2002. Increase in spinal stability obtained at levels of intra-abdominal pressure and back muscle activity realistic to work situations. *Appl. Ergon.* 33, 471–476.
- Falla, D., Rainoldi, A., Merletti, R., Jull, G., 2004. Spatio-temporal evaluation of neck muscle activation during postural perturbations in healthy subjects. *J. Electromyogr. Kinesiol.* 14, 463–474.
- Feldenkrais, M., 1999. *Awareness through Movement*. Harper, San Francisco.
- Fisk, J.D., Goodale, M.A., 1985. The organization of eye and limb movements during unrestricted reaching to targets in contralateral and ipsilateral visual space. *Exp. Brain Res.* 60, 159–178.
- Flor, H., Braun, C., Elbert, T., Birbaumer, N., 1997. Extensive reorganization of primary somatosensory cortex in chronic back pain patients. *Neurosci. Lett.* 224, 5–8.
- Forriol Campos, F., Maiques, J.P., Dankloff, C., Gomez Pellico, L., 1990. Foot morphology development with age. *Gegenbaurs Morphol. Jahrb.* 136, 669–676.
- Frank, C., Kobesova, A., Kolar, P., 2013. Dynamic neuromuscular stabilization & sports rehabilitation. *Int. J. Sports Phys. Ther.* 8, 62–73.
- Ghasemi, A., Momeni, M., Jafarzadehpour, E., Rezaee, M., Taheri, H., 2011. Visual skills involved in decision making by expert referees. *Percept Mot. Skills* 112, 161–171.
- Gibbs, J., Appleton, J., Appleton, R., 2007. Dyspraxia or developmental coordination disorder? Unravelling the enigma. *Arch. Dis. Child.* 92, 534–539.
- Gribble, P.L., Everling, S., Ford, K., Mattar, A., 2002. Hand-eye coordination for rapid pointing movements. Arm movement direction and distance are specified prior to saccade onset. *Exp. Brain Res.* 145, 372–382.
- Grossberg, S., Paine, R.W., 2000. A neural model of cortico-cerebellar interactions during attentive imitation and predictive learning of sequential handwriting movements. *Neural Netw.* 13, 999–1046.
- Hadders-Algra, M., 2004. General movements: a window for early identification of children at high risk for developmental disorders. *J. Pediatr.* 145 (Suppl. 2), S12–S18.
- Hadders-Algra, M., 2005. Development of postural control during the first 18 months of life. *Neural Plast.* 12, 99–108. discussion 263–72.
- Hägglund, G., Andersson, S., Düppe, H., Lauge-Pedersen, H., Nordmark, E., Westbom, L., 2005. Prevention of severe contractures might replace multilevel surgery in cerebral palsy: results of a population-based health care programme and new techniques to reduce spasticity. *J. Pediatr. Orthop. B* 14, 269–273.
- Henderson, S.E., Sugden, D.A., Barmett, A.L., 2007. *Movement Assessment Battery for Children – Second Edition (Movement ABC-2): Examiner's Manual*. Harcourt Assessment, London.
- Henriques, D.Y., Medendorp, W.P., Gielen, C.C., Crawford, J.D., 2003. Geometric computations underlying eye-hand coordination: orientations of the two eyes and the head. *Exp. Brain Res.* 152, 70–78.
- Hermesen-van Wanrooy, M., 2006. *Baby Moves*. Baby Moves Publications, New Zealand.
- Hodges, P., 2004. Lumbopelvic stability: a functional model of biomechanics and motor control. In: *Richardson, C. (Ed.), Therapeutic Exercise for Lumbopelvic Stabilization*. Churchill Livingstone, Edinburgh, pp. 13–28.
- Hodges, P.W., Gandevia, S.C., 2000. Changes in intra-abdominal pressure during postural and respiratory activation of the human diaphragm. *J. Appl. Phys.* 89, 967–976.

- Hodges, P.W., Eriksson, A.E., Shirley, D., Gandevia, S.C., 2005. Intra-abdominal pressure increases stiffness of the lumbar spine. *J. Biomech.* 38, 1873–1880.
- Hodges, P.W., Sapsford, R., Pengel, L.H., 2007. Postural and respiratory functions of the pelvic floor muscles. *NeuroUrol. Urodyn.* 26, 362–371.
- Hung, W.W., Pang, M.Y., 2010. Effects of group-based versus individual-based exercise training on motor performance in children with developmental coordination disorder: a randomized controlled study. *J. Rehabil. Med.* 42, 122–128.
- Imamura, M., Cassius, D.A., Fregni, F., 2009. Fibromyalgia: from treatment to rehabilitation. *Eur. J. Pain* 3, 117–122.
- Ionta, S., Heydrich, L., Lenggenhager, B., Mouthon, M., Fornari, E., Chapuis, D., Gassert, R., Blanke, O., 2011. Multi-sensory mechanisms in temporo-parietal cortex support self-location and first-person perspective. *Neuron* 70, 363–374. <http://dx.doi.org/10.1016/j.neuron.2011.03.009>.
- Kapandji, I.A., 1992. *The Physiology of the Joints. Volume Three The Trunk and the Vertebral Column*, second ed. Churchill Livingstone, Edinburgh.
- Kasai, T., Ikata, T., Katoh, S., Miyake, R., Tsubo, M., 1996. Growth of the cervical spine with special reference to its lordosis and mobility. *Spine* 21, 2067–2073.
- Katanoda, K., Yoshikawa, K., Sugishita, M., 2001. A functional MRI study on the neural substrates for writing. *Hum. Brain Mapp.* 13, 34–42.
- Kirby, A., Sugden, D.A., 2007. Children with developmental coordination disorders. *J. R. Soc. Med.* 100, 182–186.
- Kobesova, A., Kolar, P., Mlckova, J., Svehlik, M., Morris, C.E., Frank, C., Lepsikova, M., Kozak, J., 2012. Effect of functional stabilization training on balance and motor patterns in a patient with Charcot-Marie-Tooth disease. *Neuroendocrinol. Lett.* 33, 101–108.
- Kolar, P., Neuwirth, J., Sanda, J., Suchanek, V., Svata, Z., Volejnik, J., Pivec, M., 2009. Analysis of diaphragm movement, during tidal breathing and during its activation while breath holding, using MRI synchronized with spirometry. *Physiol. Res.* 58, 383–392.
- Kolar, P., Sulc, J., Kyncl, M., Sanda, J., Neuwirth, J., Bokarius, A.V., Kriz, J., Kobesova, A., 2010. Stabilizing function of the diaphragm: dynamic MRI and synchronized spirometric assessment. *J. Appl. Phys.* 109, 1064–1071.
- Kolar, P., Sulc, J., Kyncl, M., Sanda, J., Cakrt, O., Andel, R., Kumagai, K., Kobesova, A., 2011. Postural function of the diaphragm in persons with and without chronic low back pain. *J. Orthop. Sports Phys. Ther.* 42, 352–362.
- Kolář, P., Kobesová, A., 2010. Postural – locomotion function in the diagnosis treatment of movement disorders. *Clin. Chiropractic* 13, 58–68.
- Koman, L.A., Smith, B.P., Shilt, J.S., 2004. Cerebral palsy. *Lancet* 363, 1619–1631.
- Lewit, K., 2010. Chain reactions in the light of developmental kinesiology. In: Lewit, K. (Ed.), *Manipulative Therapy Musculoskeletal Medicine*. Elsevier, London, pp. 157–162.
- Lord, M.J., Ogden, J.A., Ganey, T.M., 1995. Postnatal development of the thoracic spine. *Spine* 20, 1692–1698.
- McGill, S.M., McDermott, A., Fenwick, C.M., 2009. Comparison of different strongman events: trunk muscle activation and lumbar spine motion, load, and stiffness. *J. Strength Cond. Res.* 23, 1148–1161.
- Metcalfe, J.S., McDowell, K., Chang, T.Y., Chen, L.C., Jeka, J.J., Clark, J.E., 2005. Development of somatosensory-motor integration: an event-related analysis of infant posture in the first year of independent walking. *Dev. Psychobiol.* 46, 19–35.
- Mon-Williams, M., Tresilian, J.R., Wann, J.P., 1999. Perceiving limb position in normal and abnormal control: an equilibrium point perspective. *Hum. Mov. Sci.* 18, 397–419.
- Moreno, F.J., Luis, V., Salgado, F., García, J.A., Reina, R., 2005. Visual behavior and perception of trajectories of moving objects with visual occlusion. *Percept Mot. Skills* 101, 13–20.
- Morrell, D.S., Pearson, J.M., Sauser, D.D., 2002. Progressive bone and joint abnormalities of the spine and lower extremities in cerebral palsy. *Radiographics* 22, 257–268.
- Murphy, T., Woodrum, D., 1998. Functional development of respiratory muscles. In: Polin, R.A., Fox, W.W. (Eds.), *Fetal and Neonatal Physiology*, vol. 1. WB Saunders Company, Philadelphia, pp. 1071–1084.
- Novotny, J.E., Beynon, B.D., Nichols, C.E., 2000. Modeling the stability of the human glenohumeral joint during external rotation. *J. Biomech.* 33, 345–354.
- Orth, H., 2005. *Das Kind in der Vojta-Therapie*. Elsevier GmbH, Urban & Fischer Verlag, München.
- Palmer, M.M., Crawley, K., Blanco, I.A., 1993. Neonatal oral-motor assessment scale: a reliability study. *J. Perinatol.* 13, 28–35.
- Piccolini, O., Albisetti, W., Cozzaglio, M., Spreafico, F., Mosca, F., Gasparroni, V., 2009. “Postural Management” to prevent hip dislocation in children with cerebral palsy. *Hip Int.* 6 (Suppl. 19), S56–S62.
- Polatajko, H.J., Cantin, N., 2005. Developmental coordination disorder (dyspraxia): an overview of the state of the art. *Semin. Pediatr. Neurol.* 12, 250–258.
- Poulsen, A.A., Ziviani, J.M., Johnson, H., Cuskelly, M., 2008. Loneliness and life satisfaction of boys with developmental coordination disorder: the impact of leisure participation and perceived freedom in leisure. *Hum. Mov. Sci.* 27, 325–343.
- Precht, H.F., 1997. *The Neurological Examination of the Full-term Newborn Infant*. In: *Clinics in Developmental Medicine*, second ed., vol. 63. SIMP/Heinemann, London.
- Precht, H.F., Einspieler, C., Cioni, G., Bos, A.F., Ferrari, F., Sontheimer, D., 1997. An early marker for neurological deficits after perinatal brain lesions. *Lancet* 349, 1361–1363.
- Schott, N., Alof, V., Hultsch, D., Meermann, D., 2007. Physical fitness in children with developmental coordination disorder. *Res. Q. Exerc. Sport* 78, 438–450.
- Vojta, V., 1972a. Early diagnosis and therapy of cerebral motor disorders in childhood. A. Postural reflexes in developmental kinesiology. I. Normal developmental stages. *Z. Orthop. Ihre. Grenzgeb.* 110, 450–457.
- Vojta, V., 1972b. Early diagnosis and therapy of cerebral motor disorders in childhood. A. Postural reflexes in developmental kinesiology. 2. Pathologic reactions. *Z. Orthop. Ihre. Grenzgeb.* 110, 458–466.
- Vojta, V., 2008. *Die zerebralen Bewegungsstörungen im Säuglingsalter: Frühdiagnose und Frühtherapie (Broschiert)*. Thieme, Stuttgart.
- Vojta, V., Schweizer, E., 2009. *Die Entdeckung der idealen Motorik*. Richard Pflaum Vlg GmbH.
- Volpon, J.B., 1994. Footprint analysis during growth period. *J. Pediatr. Orthop.* 14, 83–85.
- Wilson, B.N., Polatajko, H.J., Kaplan, B.J., Faris, P., 1995. Use of the Bruininks-Oseretsky test of motor proficiency in occupational therapy. *Am. J. Occup. Ther.* 49, 8–17.
- Zafeiriou, D.I., 2004. Primitive reflexes and postural reactions in the neurodevelopmental examination. *Pediatr. Neurol.* 31, 1–8.