

Elbow Ulnar Collateral Ligament Injuries in Throwing Athletes: Diagnosis and Management

Max D. Gehrman, MD,* Louis C. Grandizio, DO*



CME INFORMATION AND DISCLOSURES

The Journal of Hand Surgery will contain at least 2 clinically relevant articles selected by the editor to be offered for CME in each issue. For CME credit, the participant must read the articles in print or online and correctly answer all related questions through an online examination. The questions on the test are designed to make the reader think and will occasionally require the reader to go back and scrutinize the article for details.

The JHS CME Activity fee of \$15.00 includes the exam questions/answers only and does not include access to the JHS articles referenced.

Statement of Need: This CME activity was developed by the JHS editors as a convenient education tool to help increase or affirm reader's knowledge. The overall goal of the activity is for participants to evaluate the appropriateness of clinical data and apply it to their practice and the provision of patient care.

Accreditation: The American Society for Surgery of the Hand (ASSH) is accredited by the Accreditation Council for Continuing Medical Education (ACCME) to provide continuing medical education for physicians.

AMA PRA Credit Designation: The ASSH designates this Journal-Based CME activity for a maximum of 1.00 *AMA PRA Category 1 Credits*[™]. Physicians should claim only the credit commensurate with the extent of their participation in the activity.

ASSH Disclaimer: The material presented in this CME activity is made available by the ASSH for educational purposes only. This material is not intended to represent the only methods or the best procedures appropriate for the medical situation(s) discussed, but rather it is intended to present an approach, view, statement, or opinion of the authors that may be helpful, or of interest, to other practitioners. Examinees agree to participate in this medical education activity, sponsored by the ASSH, with full knowledge and awareness that they waive any claim they may have against the ASSH for reliance on any information presented. The approval of the US Food and Drug Administration (FDA) is required for procedures and drugs that are considered experimental. Instrumentation systems discussed or reviewed during this educational activity may not yet have received FDA approval.

Provider Information can be found at <http://www.assh.org/About-ASSH/Contact-Us>.

Technical Requirements for the Online Examination can be found at <https://jhandsurg.org/cme/home>.

Privacy Policy can be found at <http://www.assh.org/About-ASSH/Policies/ASSH-Policies>.

ASSH Disclosure Policy: As a provider accredited by the ACCME, the ASSH must ensure balance, independence, objectivity, and scientific rigor in all its activities.

Disclosures for this Article

Editors

Dawn M. LaPorte, MD, has no relevant conflicts of interest to disclose.

Authors

All authors of this journal-based CME activity have no relevant conflicts of interest to disclose. In the printed or PDF version of this article, author affiliations can be found at the bottom of the first page.

Planners

Dawn M. LaPorte, MD, has no relevant conflicts of interest to disclose. The editorial and education staff involved with this journal-based CME activity has no relevant conflicts of interest to disclose.

Learning Objectives

Upon completion of this CME activity, the learner will understand:

- The anatomy and biomechanics of the ulnar collateral ligament of the elbow.
- How to diagnose ulnar collateral ligament injuries of the elbow.
- Nonoperative and operative management for injuries of the ulnar collateral ligament of the elbow.

Deadline: Each examination purchased in 2022 must be completed by January 31, 2023, to be eligible for CME. A certificate will be issued upon completion of the activity. Estimated time to complete each JHS CME activity is up to one hour.

Copyright © 2022 by the American Society for Surgery of the Hand. All rights reserved.

Ulnar collateral ligament (UCL) injuries of the elbow are common in overhead throwing athletes. With throwing, the elbow experiences substantial valgus stress and repetitive microtrauma can lead to injury. Increasing rates of injury among both youth and professional throwers has resulted in a “UCL epidemic.” Ulnar collateral ligament reconstruction (“Tommy John Surgery”) became a part of the public consciousness after Tommy John

From the *Department of Orthopaedic Surgery, Geisinger Commonwealth School of Medicine, Geisinger MSKI, Danville, PA.

Received for publication April 1, 2021; accepted in revised form November 15, 2021.

No benefits in any form have been received or will be received related directly or indirectly to the subject of this article.

Corresponding author: Louis C. Grandizio, DO, Department of Orthopaedic Surgery, Geisinger Commonwealth School of Medicine, Geisinger MSKI, 21-30, 100 N Academy Ave, Danville, PA 17822; e-mail: chris.grandizio@gmail.com.

0363-5023/22/4703-0008\$36.00/0
<https://doi.org/10.1016/j.jhsa.2021.11.026>

returned to professional baseball after a UCL reconstruction with Dr Frank Jobe for what was once considered a career-ending injury. Partial tears and some athletes with complete UCL injuries can be managed without surgery. Since the introduction of UCL reconstruction, technical modifications have aimed to decrease complications and increase return-to-play rates. Ulnar collateral ligament repair has reemerged as a potential surgical option for some throwers. Future prospective and comparative studies are necessary to better define the optimal operative treatment for these injuries. (*J Hand Surg Am.* 2022;47(3):266–273. Copyright © 2022 by the American Society for Surgery of the Hand. All rights reserved.)

Key words Elbow surgery, tommy john, UCL reconstruction, UCL repair, ulnar collateral ligament.



INJURIES TO THE ULNAR COLLATERAL ligament (UCL) of the elbow in overhead throwing athletes were first described in 1946, when Waris¹ reported on UCL ruptures in high-level javelin throwers. Ulnar collateral ligament reconstruction (“Tommy John Surgery”) became increasingly popularized after pitcher Tommy John returned to pitching professionally after a UCL reconstruction with Dr Frank Jobe in 1974. In the decades following, surgical options have continued to evolve, and return-to-play (RTP) rates have risen to around 85%.² However, despite an improved understanding of UCL biomechanics, rates of injury and reconstruction have substantially increased in recent years, resulting in a “UCL epidemic.”³

ANATOMY AND BIOMECHANICS

The UCL has 3 major components: anterior, posterior, and transverse bundles (Fig. 1).⁴ The anterior bundle is the primary restraint to valgus forces. The anterior bundle is further divided into anterior and posterior bands, of which the anterior band is the primary valgus restraint.⁵ The origin of the anterior bundle is located on the anterior-inferior aspect of the medial epicondyle. Its insertion is nearly 30 mm in length along an osseous ridge (UCL ridge) extending distally from the sublime tubercle to just medial to the ulnar insertion of the brachialis tendon (Fig. 1).^{4,5} The proximal aspect of the UCL receives its blood supply from the recurrent flexor or pronator artery and is well vascularized.⁶ However, the distal insertion is relatively hypovascular.⁶ In addition to the static constraint provided by the UCL, the muscles of the medial elbow function as dynamic valgus stabilizers.

Injury to the UCL is often the result of repetitive microtrauma from tensile forces exerted on the medial elbow during throwing.^{2,7} Tears are most

common proximally. Maximum valgus force occurs during the late cocking and early acceleration phase of throwing, and the mechanics of the remainder of the upper limb and core (functioning as a kinetic chain) can determine the amount of energy transmitted across the medial elbow.⁸

INJURY PREVENTION

Ulnar collateral ligament injury rates have increased for both professional pitchers and youth throwers.³ UCL injury prevention has increasingly been the subject of research investigations and lay-press reports. The American Sports Medicine Institute (ASMI) released an evidence-based position statement identifying both risk factors and common misconceptions about UCL injuries.³ They identified risk factors such as pitching on multiple teams, pitching year-round, and poor mechanics or conditioning as risk factors for youth injury.³ Youth pitchers who throw >100 innings a year are 3.5 times more likely to sustain an injury.⁹ Misconceptions regarding these injuries and guidelines are commonplace. Ahmad et al¹⁰ demonstrated that around a quarter of parents and players did not believe pitch counts were associated with higher rates of UCL injury. Throwing a curveball is not strongly associated with UCL injuries; however, many organizations encourage young pitchers to develop a change-up as a secondary pitch prior to a curveball.^{3,11} Little League baseball has implemented pitch counts and evidenced-based recommendations (Table 1) to help combat the rising rates of injury; however, further studies are required to better understand their effectiveness.¹²

DIAGNOSIS

Clinical presentation

Patients with both acute and chronic injuries will report medial elbow pain. Throwers with an acute

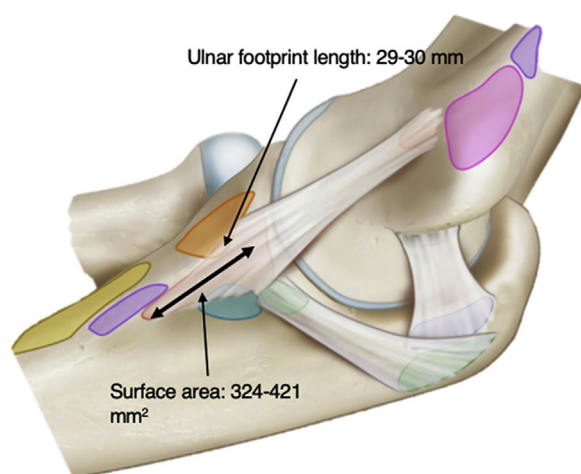


FIGURE 1: Illustration of the anterior, posterior, and transverse UCL bundles on the medial elbow. Included are the footprint length and surface area of the UCL insertion along the sublime tubercle and the UCL ridge. Double sided black arrows indicate the location of the UCL footprint. Reproduced with permission from Springer Nature.⁶

injury will often recall either hearing or feeling a “pop” during a particular throw. In the chronic setting, decreases in both velocity and accuracy may be noted. Athletes can present with signs and symptoms of ulnar nerve compression at the elbow, and these changes are more frequently sensory than motor. Surgeons need to maintain a high index of suspicion for both associated and differential diagnoses when evaluating athletes with medial elbow pain (Table 2).

Physical examination

As part of a kinetic chain, an examination of the entire upper extremity is important when evaluating athletes with suspected UCL injuries. We test cervical range of motion and assess for clinical evidence of cervical radiculopathy. After assessing for any evidence of scapular dyskinesia, we measure shoulder range of motion in the supine position in order to better isolate glenohumeral motion. Pitchers with increased shoulder external rotation have greater medial elbow torque with throwing.¹³ A careful neurologic examination can reveal evidence of associated ulnar neuropathy, particularly with more chronic injuries.

An examination of the elbow includes assessments of active and passive range of motion. Throwers, particularly baseball pitchers, often have slight elbow flexion contractures on the throwing arm relative to the nondominant side, which is typically

asymptomatic.¹⁴ Palpation should include the medial elbow structures, including the medial epicondyle, flexor-pronator mass, sublime tubercle, medial head of the triceps, and ulnar nerve. A physical examination of ulnar nerve instability at the elbow demonstrates poor agreement with intraoperative nerve findings.¹⁵ The incidence of ulnar nerve compression associated with UCL injuries has been variably reported. Prior authors have suggested that ulnar nerve neuritis can be associated with valgus elbow instability in over 40% of cases.¹⁶ In their series of UCL reconstructions, Cain et al¹⁷ noted that one-third of their patients had a positive Tinel sign over the ulnar nerve at the elbow; however, only 3% had persistent ulnar nerve paresthesias before surgery. When concomitant ulnar nerve pathology is suspected, we routinely obtain preoperative electrodiagnostic studies. In cases with associated nerve pathology, an ulnar nerve decompression can be performed at the time of UCL reconstruction; however, indications for transposition remain controversial.

Valgus stability tests should be performed on both sides for comparison, as differences can be subtle. Valgus stress in full extension engages the olecranon into the olecranon fossa, which can aid in valgus stability. Pain with moving the elbow passively into full extension while applying a valgus force can be indicative of valgus extension overload syndrome, with the associated posterior medial olecranon osteophyte. The valgus stress test, which is performed at 30° of elbow flexion, unlocks the olecranon from the olecranon fossa and can stress the anterior band of the UCL (Fig. 2A). The moving valgus stress test and milking maneuver (Fig. 2B) can also assess valgus stability. Pain or apprehension when performing these stability tests should be noted, as subtle 2-mm differences in medial elbow gapping can be challenging to appreciate on exam.

Imaging

Standard elbow radiographs should be obtained, which can reveal avulsion fractures, posterior medial olecranon osteophytes associated with valgus extension overload syndrome, osteochondral lesions, as well as ossicles and calcifications within the UCL. Standardized stress radiographs with comparison to the uninjured side can reveal increased medial joint gapping and aid in the diagnosis of a complete UCL injury. While increased medial laxity is associated with UCL injury, throwers can have slight increases in medial laxity that are adaptive.¹⁸ An ultrasound can be utilized as a dynamic test to assess the UCL

TABLE 1. Little League Baseball Pitch Counts and Rest Requirements

Age	Daily Maximum Pitches	Required Rest*				
		0 Days	1 Day	2 Days	3 Days	4 Days
7–8	50	1–20	21–35	36–50	N/A	N/A
9–10	75	1–20	21–35	36–50	51–65	66+
11–12	85	1–20	21–35	36–50	51–65	66+
13–14	95	1–20	21–35	36–50	51–65	66+
15–16	95	1–30	31–45	46–60	61–75	76+

*Required rest days are based on the number of pitches thrown, as well as the age of the player.

TABLE 2. Differential Diagnoses and Associated Diagnoses for Overhead Athletes Presenting With Medial Elbow Pain or UCL Injuries

Differential Diagnosis and Associated Conditions in the Evaluation of Elbow UCL Injuries
Cubital tunnel syndrome or ulnar neuropathy
Flexor-pronator muscle strain
Osteochondral lesions
Medial epicondyle apophysitis
Valgus extension overload syndrome
Snapping medial triceps
Olecranon stress fracture
Medial epicondyle avulsion
Cervical radiculopathy
Elbow arthritis

thickness, integrity, and joint gapping with a valgus stress. An ultrasound is noninvasive and can quantify laxity but is user-dependent and requires a familiarity with the appropriate techniques.

Magnetic resonance imaging arthrograms can aid in distinguishing complete from partial tears and remain our preferred imaging modality for suspected UCL injuries. The “T-Sign” can be indicative of a partial tear, where dye extravasates along the humerus or sublime tubercle, yet remains contained under the most superficial portion of the UCL. Magnetic resonance imaging classification systems can aid in guiding treatment decisions and have demonstrated higher levels of inter- and intra-observer agreement.¹⁹ The 6-part classification system proposed by Ramkumar et al¹⁹ defines the tear location on a magnetic resonance image (1 = proximal, 2 = midsubstance, 3 = distal) and distinguishes partial tears (subtype A) from complete tears (subtype B).

NONSURGICAL MANAGEMENT

Nonsurgical management is the treatment of choice for partial-thickness UCL tears. Athletes with full-thickness tears may elect to undergo an attempt at nonsurgical management, particularly if the time associated with postoperative rehab would be detrimental. Athletes that do not wish to continue throwing do not need to undergo UCL reconstruction. Ulnar-based tears are significantly more likely to fail nonsurgical management compared to proximally based tears.²⁰ Among professional pitchers, RTP rates for partial tears are around 85% with nonsurgical treatment.²¹

During the initial period of nonsurgical treatment, we have the athlete refrain from throwing and focus on addressing any associated deficits, such as glenohumeral internal rotation deficit, scapular dyskinesia or SICK (scapular malpositioning, inferior medial border prominence, coracoid pain, and dyskinesia of scapular movement), or core and hip girdle weakness. When the elbow is pain free, we initiate flexor-pronator strengthening and begin a throwing program with close supervision with the therapist or trainer. Attention is focused on optimizing pitching mechanics during this period.

Platelet-rich plasma has been frequently described as an adjuvant to nonsurgical treatment, but there are a paucity of prospective, randomized trials supporting its use. Prior series have suggested increased healing rates with platelet-rich plasma, but a recent case-control investigation of professional pitchers receiving platelet-rich plasma injections did not improve RTP outcomes with nonsurgical treatment.²²

OPERATIVE MANAGEMENT

Surgical indications for UCL tears in overhead athletes include partial tears with persistent symptoms after nonsurgical treatment, as well as symptomatic

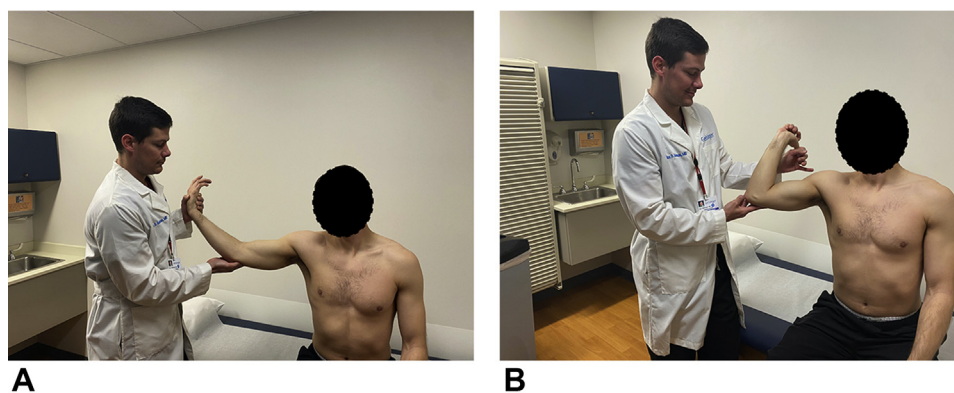


FIGURE 2: Both **A** the valgus stress test and **B** the milking maneuver can be used to assess UCL instability. **A** The valgus stress test is performed with the elbow in 30° of flexion with a valgus force applied by the examiner. **B** With the milking maneuver, the forearm is supinated and the shoulder is abducted while the elbow is placed at or above 90° of flexion. The examiner applies a posteriorly directed force while holding the patient's thumb, which places a valgus stress across the elbow.

complete tears. Surgical options include UCL repair and reconstruction. In addition to throwing athletes, some nonthrowing athletes may benefit from operative treatment of these injuries. For example, rock climbers, wrestlers, and competitive gymnasts often bear weight through the upper extremity and may have functional instability and pain associated with UCL injuries.

UCL repair

Ulnar collateral ligament repair has reemerged as a potential surgical option for some athletes with UCL injuries. Indications for this procedure are continuing to evolve and remain controversial. Early experience with this technique resulted in high rates of failure compared to reconstruction, leading some authors to abandon UCL repair entirely.¹⁷ However, more recent series have demonstrated RTP rates above 90%.^{8,23,24} Ulnar collateral ligament repair has the potential advantage of a shorter rehabilitation prior to the resumption of throwing. In the absence of randomized studies analyzing repair versus reconstruction, we individualize this decision based on age, the goals of the patient, and the characteristics of the tear. In our practice, repair is considered for athletes with partial-thickness UCL tears who fail to return to sport with nonsurgical treatment. Additionally, we consider repair in cases of full-thickness avulsions from the humeral origin or ulnar insertion, particularly in younger athletes. We augment the repair with braided, nonabsorbable suture tape, similar to that described by Dugas et al²³ (Fig. 3). We agree with prior authors that midsubstance tears, intrasubstance ossicles, and generally poor or attenuated ligament quality are often better addressed with

reconstruction.^{8,23} Additionally, patient factors should be considered in cases where the tear pattern is potentially amenable to repair. For example, a high school junior pitcher without college aspirations who desires to compete in their senior season may be more interested in repair with the potentially shorter rehabilitation period. In these cases, shared decision-making can help guide treatment.

UCL reconstruction: technique history and evolution

Techniques for UCL reconstruction have undergone a number of modifications since the 1970s. Dr Frank Jobe described a UCL reconstruction utilizing a flexor-pronator tenotomy and a routine submuscular transposition of the ulnar nerve. This “Jobe Technique” utilized a figure-of-8 autograft through drill tunnels in the ulna and humerus (Fig. 4). Jobe reported an RTP rate of 63% in his series of 16 patients.²⁵ Subsequent modifications aimed to decrease the high rate of ulnar nerve complications. The Modified Jobe Technique favored a muscle-splitting approach as a means of avoiding some of the morbidity associated with flexor-pronator tenotomy. Additionally, with the Modified Jobe Technique, routine transposition of the ulnar nerve was no longer performed. Thompson et al²⁶ demonstrated improvements with respect to RTP (>90%) and ulnar nerve complications with the Modified Jobe Technique.

Dr Andrews described the ASMI Technique, with a flexor-pronator elevation between the 2 heads of the flexor carpi ulnaris and a figure-of-8 graft.¹⁷ In a series of 1,281 patients who underwent reconstruction with the ASMI Technique, Cain et al¹⁷ demonstrated an RTP rate of 83%. Compared to the original Jobe Technique, the ASMI Technique employs

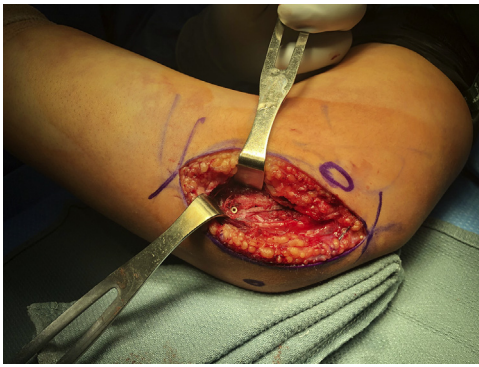


FIGURE 3: Ulnar collateral ligament repair augmented with braided, nonabsorbable suture-tape material.

routine subcutaneous, as opposed to submuscular, transposition of the ulnar nerve, which appeared to decrease the overall complication rate.¹⁷ Other reconstruction techniques, notably the Docking technique, have been the focus of a number of investigations as well. Utilizing a muscle-splitting approach, the Docking technique involves 2 converging tunnels in the ulna and a single humeral docking tunnel for graft passage (Fig. 4). Proposed advantages include less ulnar nerve and flexor-pronator morbidity, as well as a simplified method of graft passage and tensioning. Excellent results have been reported in greater than 90% of patients, with ulnar nerve complications occurring in less than 3% in large series.^{2,27}

More recent technical modifications have often endeavored to simplify graft management and often utilize implants for graft fixation. The David Altchek, Neal ElAttrache, Tommy John (DANE TJ) technique utilizes a proximal Docking technique with interference screw fixation in the ulna (Fig. 4). Proposed advantages of the DANE TJ technique include creating an isometric and more anatomic distal insertion, as well as a decreased risk of bone bridge fracture and fixation failure by using an interference screw in the ulna.²⁸ Other techniques have employed all suspensory endobutton fixation, as well as all interference screw fixation, which may have some biomechanical advantages.²⁹

A lack of prospective and randomized studies analyzing the various operative techniques makes comparisons difficult. Systematic reviews have suggested that complication minimization can lead to increased RTP.³⁰ A recent systematic review and meta-analysis demonstrated no significant difference outcomes between the Modified Jobe and Docking Techniques when a muscle-splitting approach was

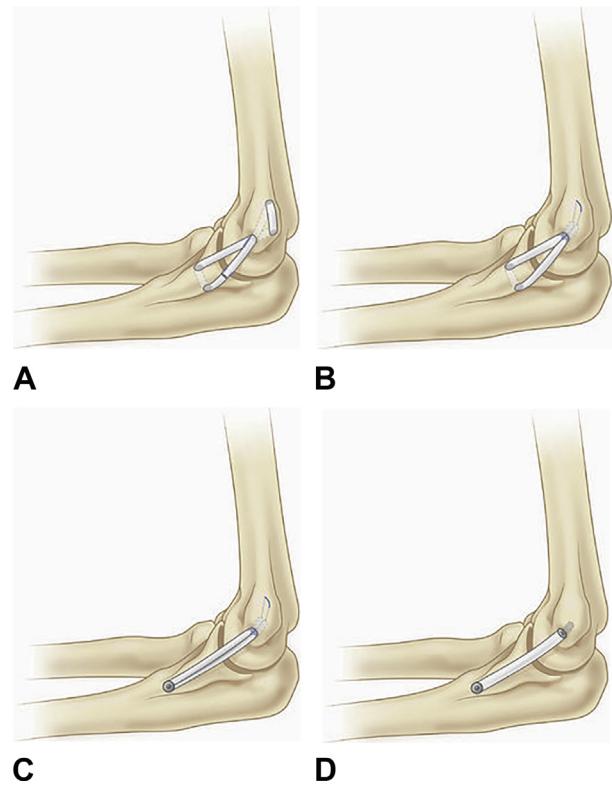


FIGURE 4: Illustrations of 4 common UCL reconstruction techniques: A Jobe Technique with a figure-of-8 graft, B the Docking technique, C the David Altchek, Neal ElAttrache, Tommy John Technique, and D the Dual Interference Screw technique.

used without routine submuscular transposition.³¹ As a result, routine ulnar nerve transposition is now rarely performed in the absence of symptomatic ulnar nerve compression.

Complications

As UCL reconstruction techniques have moved away from flexor-pronator tenotomies and routine submuscular transposition, complication rates have generally decreased. Ulnar neuropathy is a frequent complication, with a rate of 12% across all published series.³² Additional neurologic complications can include injuries to the medial antebrachial cutaneous nerve. During palmaris autograft harvest, care must be taken to protect the median nerve because iatrogenic nerve injury is a well-described and devastating complication associated with this procedure.³³ Medial epicondyle or tunnel fractures are rare. Elbow stiffness and heterotopic ossification can also occur. Given the increase in the frequency of UCL reconstructions, there is subsequently an increased need for revision procedures.

AUTHOR'S PREFERRED TECHNIQUE: UCL RECONSTRUCTION

For athletes indicated for UCL reconstruction, we utilize a Docking technique similar to that described by Rohrbough et al.²⁷ We find this technique allows for reliable and reproducible graft tensioning within the humeral socket and avoids the added costs associated with fixation methods that use implants. After a peripheral nerve block and induction of general anesthesia, the patient is positioned on a regular bed with an arm board. A sterile tourniquet is utilized. Our preferred graft is an ipsilateral palmaris autograft when available; however, in some cases a hamstring allograft is used as described by Savoie et al.³⁴ A generous longitudinal skin incision is made just posterior to the medial epicondyle extending distally beyond the sublime tubercle. Branches of the medial antebrachial cutaneous nerve are identified and protected. The nerve's course can be highly variable; however, the anterior branch can often be located 2–3 cm anterior to the epicondyle. In cases where an ulnar nerve decompression is not performed, we use a muscle-splitting approach. The fascial raphe is identified between the flexor carpi ulnaris and the common flexors. Alternatively, in patients with evidence of concomitant ulnar nerve compression, we approach the UCL and sublime tubercle between the 2 heads of the flexor carpi ulnaris after the ulnar nerve has been decompressed.

A key elevator is used to expose the entire length of the UCL, and the location of the tear is determined. A longitudinal split is then made with a knife through the anterior band of the UCL, which exposes the underlying ulnohumeral joint. Elevation of the anterior and posterior leaflets of the UCL allows for visualization of the sublime tubercle, as well as the UCL ridge. Converging 3.5-mm anterior and posterior drill tunnels are spaced 1 cm apart and are located at the junction of the sublime tubercle and UCL ridge. Small, curved curettes can be used to ensure that the tunnels connect. The graft is then passed through the ulnar drill tunnels.

We next identify the UCL origin on the anterior-inferior surface of the medial epicondyle. A 4.5-mm drill is used to create the humeral tunnel, which is 15 mm in depth. Care is taken to ensure that the drill does not penetrate the far cortex of the epicondyle. While protecting the ulnar nerve, a drill guide is used to create 2 separate 2.0-mm drill holes that communicate with the humeral socket. These 2.0-mm tunnels allow for suture passage from the graft and tensioning. The graft configuration is shown in

Figure 4. Prior to tensioning the graft, we repair native UCL with 2-0 braided, nonabsorbable suture. With the forearm in supination, we tension the graft with a slight varus stress in 70° of flexion. The graft can then be sutured to the underlying native ligament for additional fixation. After wound closure, a long-arm posterior orthosis is applied in 70° of flexion until the first postoperative visit.

POSTOPERATIVE REHABILITATION

After UCL reconstruction, we use a postoperative orthosis for 10 days after surgery and encourage immediate shoulder, wrist, and digital range of motion. Gentle strengthening can begin 4 to 6 weeks after surgery, and valgus stress to the elbow is avoided for 4 months. Our throwing program begins 4 months after surgery; for pitchers, simulated games typically begin around 10 months. Full RTP is typically between 12 and 18 months after reconstruction, depending on the individual circumstances, sport, and position.

SUMMARY

The increasing rate of UCL injuries among both youth and professional athletes remains a concern. Organizations have adopted evidenced-based guidelines with respect to pitch counts in an effort to decrease UCL injuries among youth pitchers. In the decades since the introduction of UCL reconstruction, technical modifications have aimed to decrease complications and increase RTP rates. Ulnar collateral ligament repair has reemerged as a promising option for some UCL injuries and requires further analysis. Future prospective, comparative studies are necessary to better define the optimal operative treatment for these injuries.

REFERENCES

1. Waris W. Elbow injuries of javelin-throwers. *Acta Chir Scand*. 1946;93(6):563–575.
2. Bruce JR, Andrews JR. Ulnar collateral ligament injuries in the throwing athlete. *J Am Acad Orthop Surg*. 2014;22(5):315–325.
3. American Sports Medicine Institute. Position Statement for Tommy John Injuries in Baseball Pitchers. Accessed February 1, 2021. <http://www.asmi.org/research.php?page=research§ion=TJpositionstatement>
4. Cinque ME, Schickendantz M, Frangiamore S. Review of anatomy of the medial ulnar collateral ligament complex of the elbow. *Curr Rev Musculoskelet Med*. 2020;13(1):96–102.
5. Farrow LD, Mahoney AJ, Stefancin JJ, Taljanovic MS, Sheppard JE, Schickendantz MS. Quantitative analysis of the medial ulnar collateral ligament ulnar footprint and its relationship to the ulnar sublime tubercle. *Am J Sports Med*. 2011;39(9):1936–1941.
6. Buckley PS, Morris ER, Robbins CM, et al. Variations in blood supply from proximal to distal in the ulnar collateral ligament of the

- elbow: a qualitative descriptive cadaveric study. *Am J Sports Med.* 2019;47(5):1117–1123.
7. Patel RM, Lynch TS, Amin NH, Calabrese G, Gryzlo SM, Schickendantz MS. The thrower's elbow. *Orthop Clin North Am.* 2014;45(3):355–376.
 8. Torres SJ, Limpisvasti O. Ulnar collateral ligament repair of the elbow—biomechanics, indications, and outcomes. *Curr Rev Musculoskelet Med.* 2021;14(2):168–173.
 9. Fleisig GS, Andrews JR, Cutter GR, et al. Risk of serious injury for young baseball pitchers: a 10-year prospective study. *Am J Sports Med.* 2011;39(2):253–257.
 10. Ahmad CS, Grantham WJ, Greiwe RM. Public perceptions of Tommy John surgery. *Phys Sportsmed.* 2012;40(2):64–72.
 11. Keller RA, Marshall NE, Guest JM, Okoroafor KR, Jung EK, Moutzourous V. Major League Baseball pitch velocity and pitch type associated with risk of ulnar collateral ligament injury. *J Shoulder Elbow Surg.* 2016;25(4):671–675.
 12. Pytiak AV, Stearns P, Bastrom TP, et al. Are the current little league pitching guidelines adequate? A single-season prospective MRI study. *Orthop J Sports Med.* 2017;5(5):2325967117704851.
 13. Khalil LS, Jildeh TR, Taylor KA, et al. The relationship between shoulder range of motion and elbow stress in college pitchers. *J Shoulder Elbow Surg.* 2021;30(3):504–511.
 14. Wright RW, Steger-May K, Wasserlauf BL, O'Neal ME, Weinberg BW, Paletta GA. Elbow range of motion in professional baseball pitchers. *Am J Sports Med.* 2006;34(2):190–193.
 15. Rutter M, Grandizio LC, Malone WJ, Klena JC. The use of preoperative dynamic ultrasound to predict ulnar nerve stability following in situ decompression for cubital tunnel syndrome. *J Hand Surg Am.* 2019;44(1):35–38.
 16. Chen FS, Rokito AS, Jobe FW. Medial elbow problems in the overhead-throwing athlete. *J Am Acad Orthop Surg.* 2001;9(2):99–113.
 17. Cain EL, Andrews JR, Dugas JR, et al. Outcome of ulnar collateral ligament reconstruction of the elbow in 1281 athletes: results in 743 athletes with minimum 2-year follow-up. *Am J Sports Med.* 2010;38(12):2426–2434.
 18. Molenaars RJ, Medina GIS, Eygendaal D, Oh LS. Injured vs. uninjured elbow opening on clinical stress radiographs and its relationship to ulnar collateral ligament injury severity in throwers. *J Shoulder Elbow Surg.* 2020;29(5):982–988.
 19. Ramkumar PN, Frangiamore SJ, Navarro SM, et al. Interobserver and intraobserver reliability of an MRI-based classification system for injuries to the ulnar collateral ligament. *Am J Sports Med.* 2018;46(11):2755–2760.
 20. Frangiamore SJ, Lynch TS, Vaughn MD, et al. Magnetic resonance imaging predictors of failure in the nonoperative management of ulnar collateral ligament injuries in professional baseball pitchers. *Am J Sports Med.* 2017;45(8):1783–1789.
 21. Ford GM, Genuario J, Kinkartz J, Githens T, Noonan T. Return-to-play outcomes in professional baseball players after medial ulnar collateral ligament injuries: comparison of operative versus nonoperative treatment based on magnetic resonance imaging findings. *Am J Sports Med.* 2016;44(3):723–728.
 22. Chauhan A, McQueen P, Chalmers PN, et al. Nonoperative treatment of elbow ulnar collateral ligament injuries with and without platelet-rich plasma in professional baseball players: a comparative and matched cohort analysis. *Am J Sports Med.* 2019;47(13):3107–3119.
 23. Dugas JR, Looze CA, Capogna B, et al. Ulnar collateral ligament repair with collagen-dipped FiberTape augmentation in overhead-throwing athletes. *Am J Sports Med.* 2019;47(5):1096–1102.
 24. Savoie FH III, Trenhaile SW, Roberts J, Field LD, Ramsey JR. Primary repair of ulnar collateral ligament injuries of the elbow in young athletes: a case series of injuries to the proximal and distal ends of the ligament. *Am J Sports Med.* 2008;36(6):1066–1072.
 25. Jobe FW, Stark H, Lombardo SJ. Reconstruction of the ulnar collateral ligament in athletes. *J Bone Joint Surg Am.* 1986;68(8):1158–1163.
 26. Thompson WH, Jobe FW, Yocum LA, Pink MM. Ulnar collateral ligament reconstruction in athletes: muscle-splitting approach without transposition of the ulnar nerve. *J Shoulder Elbow Surg.* 2001;10(2):152–157.
 27. Rohrbough JT, Altchek DW, Hyman J, Williams RJ, Botts JD. Medial collateral ligament reconstruction of the elbow using the docking technique. *Am J Sports Med.* 2002;30(4):541–548.
 28. Conway JE. The DANE TJ procedure for elbow medial ulnar collateral ligament insufficiency. *Tech Shoulder Elb Surg.* 2006;7(1):36–43.
 29. Shah RP, Lindsey DP, Sungar GW, McAdams TR. An analysis of four ulnar collateral ligament reconstruction procedures with cyclic valgus loading. *J Shoulder Elbow Surg.* 2009;18(1):58–63.
 30. Watson JN, McQueen P, Hutchinson MR. A systematic review of ulnar collateral ligament reconstruction techniques. *Am J Sports Med.* 2014;42(10):2510–2516.
 31. Looney AM, Wang DX, Conroy CM, et al. Modified Jobe versus docking technique for elbow ulnar collateral ligament reconstruction: a systematic review and meta-analysis of clinical outcomes. *Am J Sports Med.* 2021;49(1):236–248.
 32. Clain JB, Vitale MA, Ahmad CS, Ruchelsman DE. Ulnar nerve complications after ulnar collateral ligament reconstruction of the elbow: a systematic review. *Am J Sports Med.* 2019;47(5):1263–1269.
 33. Leslie BM, Osterman AL, Wolfe SW. Inadvertent harvest of the median nerve instead of the palmaris longus tendon. *J Bone Joint Surg Am.* 2017;99(14):1173–1182.
 34. Savoie FH III, Morgan C, Yaste J, Hurt J, Field L. Medial ulnar collateral ligament reconstruction using hamstring allograft in overhead throwing athletes. *J Bone Joint Surg Am.* 2013;95(12):1062–1066.