

# Ankle Sprains: Evaluation, Rehabilitation, and Prevention

Eric T. Chen, MD;<sup>1,2</sup> Kelly C. McInnis, DO;<sup>1,2,3</sup> and Joanne Borg-Stein, MD<sup>1,2,4</sup>

## Abstract

Ankle sprains affect athletic populations at high rates. Athletes who suffer an ankle sprain frequently go on to develop persistent symptoms, resulting in significant resources spent toward treatment, rehabilitation, and prevention. A thorough clinical evaluation is necessary to ensure an accurate diagnosis and appropriate treatment prescription. This narrative review aims to present an approach to evaluation of high and low ankle sprains for athletes of all levels. The authors review the current evidence for ankle sprain treatment and rehabilitation. Strategies for prevention of recurrent sprains and return to play considerations also are discussed.

caregiver consultation and diagnosis, whereas indirect costs include time lost from sport or work (5). Verhagen et al. (6) estimated a cost of approximately US \$504 to prevent a single ankle sprain, which included expenses for equipment, bracing and taping, physical therapy, and medical evaluation. Cost sharing in team settings may reduce overall expenses associated with care; for example, an athletic trainer hired at an hourly rate may treat multiple team members simultaneously, reducing the overall cost of treatment per athlete.

## Introduction

Ankle sprains are common injuries that affect both general and athletic populations alike. More than 3 million ankle sprains presented to emergency departments in the United States during a 5-year period (1). Nearly half of all ankle sprains reported during this period occurred during athletic activity.

Recent injury surveillance data from the National Collegiate Athletic Association (NCAA) show lateral ankle sprains (LAS) to be the most common type of ankle sprain (2–4). In a 6-year study period, 2429 LAS were reported among 25 NCAA sports (2). During the same study period, only 480 high ankle sprains and 380 medial ankle sprains were reported (3,4). LAS occurred at the highest rates in men's and women's basketball with rates of 11.96 and 9.5 injuries per 10,000 athlete-exposures, respectively (2). Men's football, wrestling, and ice hockey accounted for the highest rate of high ankle sprains at 2.42, 2.11, and 1.77 injuries per 10,000 athletic exposures, respectively (3).

Direct and indirect costs related to ankle sprains are significant. Direct costs of injury include out-of-pocket expenses for

Up to 40% of patients who sustain an ankle sprain go on to develop persistent symptoms (7). Chronic ankle instability is characterized by persistent pain, swelling, feeling of “giving way,” and recurrent ankle sprains that continue at least 12 months after initial injury (8). Residual deficits in proprioception, muscular imbalance, and impaired neuromuscular control inadequately addressed at the time of initial injury may contribute to the development of chronic ankle instability after ankle sprain.

This narrative review aims to discuss relevant ankle anatomy, highlight pearls and pitfalls of clinical evaluation, and present the current evidence for the rehabilitation and prevention of ankle sprain injuries.

## Methods

A review was conducted of PubMed and Medline articles from January 2000 to July 2018 with search terms including: ankle sprain, high ankle sprain, syndesmosis sprain, LAS, inversion ankle sprain, rehabilitation, prevention, and orthobiologics.

## Anatomy and Pathogenesis

### Lateral ankle sprains

The mechanism of LAS involves talocrural plantarflexion and subtalar inversion. In this position, the narrower posterior dimension of the talus engages with the ankle mortise and reduces the bony stability of the talocrural joint. The anterior talofibular ligament (ATFL) most commonly consists of two bands separated by the vascular branches of the perforating peroneal artery (9). It is closely related to the joint capsule from the lateral malleolus to the lateral talar neck. In plantarflexion,

<sup>1</sup>Department of Physical Medicine and Rehabilitation, Spaulding Rehabilitation Hospital, Charlestown, MA; <sup>2</sup>Department of Physical Medicine and Rehabilitation, Harvard Medical School, Boston, MA; <sup>3</sup>Department of Orthopedics, Division of Sports Medicine, Massachusetts General Hospital, Boston, MA; <sup>4</sup>Department of Physical Medicine and Rehabilitation, Newton Wellesley Hospital, Newton, MA

Address for correspondence: Eric T. Chen, MD, 2nd Floor, 300 First Avenue, Charlestown, MA 02129; E-mail: echen18@partners.org.

1537-890X/1806/217-223

Current Sports Medicine Reports

Copyright © 2019 by the American College of Sports Medicine

the ATFL is under maximal stress and is vulnerable to injury with foot inversion (10). Isolated ATFL sprains occur in 70% of all LAS (11). The calcaneofibular ligament (CFL) arises from the lateral malleolus and courses obliquely toward a small tubercle on the posterior lateral calcaneus (9). It is the only lateral ankle ligament to span both the talocrural and subtalar joints. The posterior talofibular ligament (PTFL) is the least frequently injured of the three major lateral ankle ligaments. The PTFL courses posteriorly from lateral malleolus to the talus and is relaxed in plantar flexion and stressed in dorsiflexion (9).

Ligament tears may occur at their proximal attachment, mid-substance, or distal attachment. The severity of sprains is classified into three grades. Grade 1 is the least severe injury defined as stretching of the lateral ligaments, without tear. Grade 2 indicates partial tearing of one or more ligaments. Grade 3 is the most severe sprain and classifies injuries with complete disruption of all ligaments of the lateral ligamentous complex.

The most significant intrinsic risk factors for LAS are limited ankle dorsiflexion range of motion, reduced ankle proprioception, and decreased balance (12,13). These factors may reduce the ability of dynamic ankle stabilizers, namely, the peroneal tendons, to react to perturbations in ankle position and place the lateral ankle ligaments at higher risk for injury. Lower body mass index (BMI), reduced strength, coordination, and cardiorespiratory endurance also have been identified as potential risk factors for LAS (13). Finally, there is no clear consensus as to the influence of sex on the risk of ankle sprain (1,12,14).

The type of sport has been found to be the most significant extrinsic risk factor for sustaining LAS. Basketball, volleyball, and field sports have the highest incidences of LAS (12). In soccer players, level of competition, being a defender, and playing on natural grass as opposed to artificial turf increased risk for LAS (12).

### *Medial ankle sprains*

The deltoid ligament complex (DLC) is the primary medial ligamentous stabilizer of the ankle. Superficial and deep layers of the DLC resist external rotation and lateral translation of the talus, respectively. Superficial and deep layers both provide stabilization against valgus force at the ankle. The anterior and posterior tibiotalar ligaments comprise the deep layer and project from the medial malleolus to the talus, whereas the tibionavicular, tibiospring, and tibiocalcaneal ligaments comprise the superficial layer and spread in a broad fan-shaped band from the medial malleolus to the talus, spring ligament, and calcaneus (15).

Medial ankle sprains occur with forced ankle eversion and external rotation resulting in disruption and injury to the DLC. In athletic settings, this injury typically occurs as a result of contact with another player (4). Collegiate men's and women's soccer, men's football, and women's gymnastics have the highest incidence of medial ankle sprain (4).

Injuries that result in complete disruption of the DLC often occur in conjunction with lateral ankle sprains, ankle syndesmosis injuries, Maisonneuve fractures, and malleolar fractures, which prolong recovery (15). Isolated injuries to only the superficial layer of the deltoid ligament are usually rotationally stable and portend a good prognosis for recovery (16).

### *High ankle sprains*

High ankle sprain refers to injury of the ankle syndesmosis, which collectively includes the anterior-inferior tibiofibular ligament (AITFL), posterior-inferior tibiofibular ligament, interosseous ligament, and the transverse tibiofibular ligament. The ankle syndesmosis functions to prevent separation of the tibia and fibula and to maintain the stability of the ankle mortise. Syndesmosis injuries frequently coexist with medial ankle sprains due to their common mechanism of injury. Forceful external rotation with the foot in dorsiflexion causes the talus to separate the fibula from the tibia, resulting in injury to the syndesmosis and ankle diastasis (17). Men's football, wrestling, and ice hockey are sports with the highest risk of high ankle sprain (3).

## Clinical Evaluation

### *Presentation*

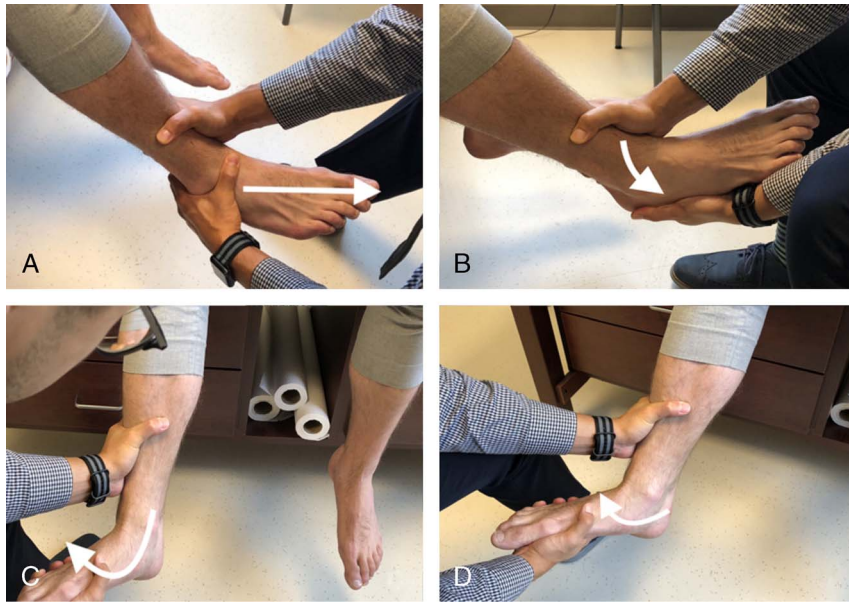Clinical evaluation of the ankle begins with a detailed and systematic history. A mechanism involving plantarflexion and inversion of the foot is suggestive of lateral ankle injury. More severe injuries with this mechanism also may involve the medial ankle. Syndesmosis and deltoid ligament injuries most commonly occur with an external rotation force applied to a fixed foot. The ability to bear weight immediately after injury may influence the decision to order standard plain films of the ankle, including anterior/posterior (A/P), lateral, and mortise views. If ankle sprain is suspected, the clinician should investigate risk factors such as prior history of ankle sprains or ankle instability, specific sport or activity during which the injury occurred, playing surface, footwear and the use of bracing or taping. The specific location of pain, presence of local or diffuse swelling, mechanical symptoms, and paresthesia should be elucidated.

### *Physical Examination*

Physical examination of the ankle should follow the fundamentals of any peripheral joint examination. The clinician should look for any obvious deformity or asymmetry that may suggest fracture or dislocation. Edema or ecchymosis may be visually apparent after acute ankle sprain. Evaluation of foot and lower limb alignment in standing may help the clinician to identify biomechanical risk factors for ankle injury.

Surface landmark palpation is particularly important in the ankle examination as specific points of tenderness may help guide the decision whether or not to obtain imaging. Based on the Ottawa Ankle Rules, X-rays are indicated if there is pain in the malleolar zone with the inability to bear weight for four steps immediately and in the emergency department or bone tenderness at the posterior edge of tip of the medial or lateral malleolus (18).

Range of motion of the ankle should be tested with the knee in both flexion and extension. Normal ankle dorsiflexion is 10 degrees with the knee extended and approximately 20 degrees with the knee flexed (19). Subtalar motion is assessed with the ankle in a neutral position. Side-to-side comparison is helpful as subtalar inversion and eversion vary widely among individuals (19). Manual muscle testing of plantar flexion, dorsiflexion, inversion, and eversion should be completed in conjunction with a neurovascular screening.



**Figure 1:** (A) Anterior drawer test, (B) Talar tilt test, (C) and (D) Kleiger external rotation test.

Special tests to stress the lateral ligaments of the ankle attempt to detect instability of the talus in relation to the distal tibia and fibula. The anterior drawer test assesses the integrity of the ATFL. With the knee and ankle both positioned at 90 degrees, the clinician uses one hand to stabilize the distal tibia while using the other hand to grasp the heel posteriorly and talus anteriorly and apply an anteriorly directed force to translate the talus anteriorly in relation to the tibia (Fig. 1). Increased laxity or translation as perceived by the examiner compared to the contralateral ankle constitutes a positive test. Validation studies have found the anterior drawer test has a sensitivity of 80% to 95% and a specificity of 74% to 84% for ligament rupture (19). Sensitivity and specificity of the anterior drawer test is optimized when performed 4 to 5 d postinjury (12). The anterolateral drawer test requires an internal rotation force while translating the talus anteriorly. Cadaveric studies found that lateral displacement of the talus greater than 3 mm in comparison to the uninjured side was 100% sensitive and 100% specific for lateral ligament rupture (19). Finally, the talar tilt test serves to detect subtalar instability by applying a supination force to the calcaneus. Up to 25 degrees of tilt between the articular surfaces of the tibia and talus may be considered normal (19). The sensitivity and specificity of the talar tilt test for detecting injury to the CFL has not been validated in the literature.

Ankle external rotation, syndesmotic ligament palpation, and proximal tibiofibular squeeze attempt to provoke pain and instability related to ankle syndesmosis injuries. With the external rotation test, also known as the Kleiger test, the clinician stabilizes the lower leg proximal to the ankle while maintaining maximal ankle dorsiflexion and applying an external rotation force to the forefoot. Reproduction of pain over the ankle syndesmosis is a positive test. Medial ankle pain with this test also may indicate deltoid ligament injury. Validation studies show the external rotation test provides a sensitivity of 68% to 71% and a specificity of 63% to 83% (19). Direct palpation of the AITFL and ankle syndesmosis yields 83% to 92% sensitivity and 29% to 63% specificity;

however, false positives are possible due to the close proximity of the ATFL (19). Pain with compression of the tibia and fibula at the midpoint of the lower leg is not highly sensitive, 29% to 39%, but provides a high degree of specificity, 88% to 89%, for detecting syndesmosis injuries (19) (Fig. 1).

The neurovascular examination should screen for peripheral nerve injury (superficial peroneal, deep peroneal, and sural nerves) and ensure peripheral pulses are intact and symmetric (dorsalis pedis and posterior tibial arteries). The exact incidence of peroneal nerve injury is not known; however, peroneal nerve injuries have been associated with higher grade ankle sprains (20). Isolated superficial peroneal neuralgia may present with preserved strength in ankle dorsiflexors with sensory deficit of the dorsal foot that spares the first dorsal web space.

## Imaging

### X-Rays

The primary purpose of plain films in the setting of acute ankle sprains is to rule out acute fracture. Fracture is detected in only 15% of X-rays taken in the setting of acute ankle sprain (18). The Ottawa Ankle Rules are highly sensitive tools for detecting fracture in the setting of acute ankle sprain (18) (Table 1). Clinicians should apply these rules to reduce unnecessary A/P, lateral, and mortise views for cases with an inversion injury mechanism when fracture is suspected.

Talar stress views of the ankle allow for detection of lateral instability by obtaining a mortise view of the ankle while placing the ankle in plantarflexion and inversion. Stress views are generally unnecessary to make the diagnosis of LAS.

In contrast, external rotation stress views may be helpful in establishing the diagnosis of syndesmosis or deltoid ligament injuries (21). External rotation stress views call for the application of an external rotation force to the ankle while obtaining an A/P view of the ankle. The medial clear space width is measured as the

**Table 1.**  
**The Ottawa ankle rules.**

Malleolar zone pain AND any one of the following criteria:
Inability to walk four steps immediately after injury or in the emergency department
Tenderness along the distal 6 cm of posterior half of the tibia or the tip of the medial malleolus
Tenderness along the distal 6 cm of posterior half of the fibula or the tip of the lateral malleolus

X-rays of the ankle are indicated when the above criteria are satisfied.

distance between the talus and medial malleolus; a width of 4 mm or greater is suggestive of deep deltoid ligament rupture (22).

### Ultrasound

The use of ultrasound for imaging the ankle is well described (23). Point of care ultrasound is as accurate as magnetic resonance imaging (MRI) in identifying major ligament injury in emergency department settings (24). Furthermore, ultrasound allows clinicians to obtain dynamic views of the ankle to identify functional deficiencies or joint instability that would not be possible with other imaging modalities. However, its accuracy in diagnosing acute ankle sprains is highly dependent on operator expertise and results should be taken in context (21) (Fig. 2).

### MRI

MRI remains the gold standard for imaging the ligamentous and intra-articular structures of the ankle (21). However, the high incidence of ankle sprains, false-positive findings, limited

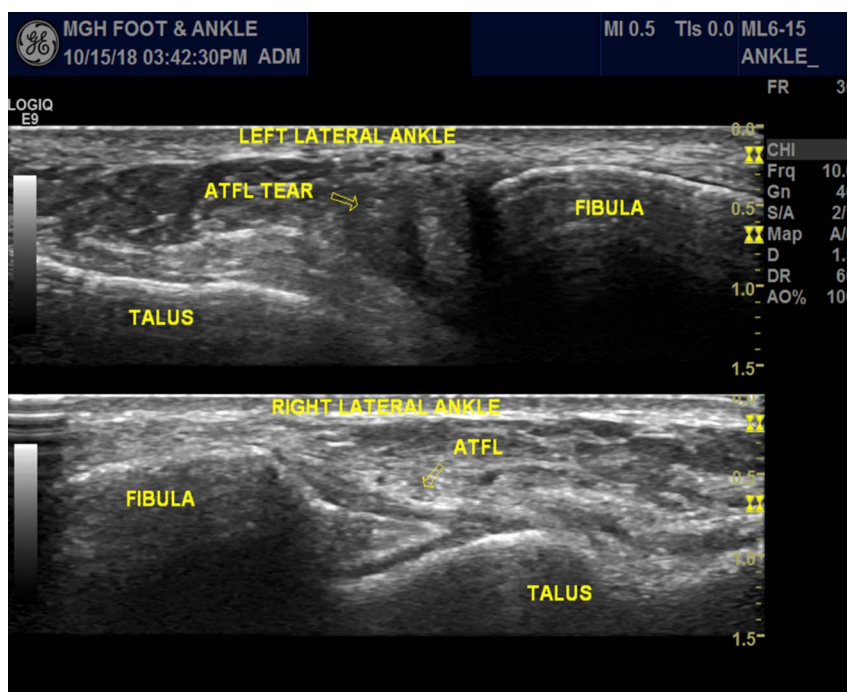
availability, and high cost limit the use of MRI in the routine management of acute ankle sprains. Clinicians should reserve MRI for cases of persistent symptoms and chronic ankle instability to rule out osteochondral defects, missed syndesmotic injuries, or osseous injuries not identified on radiograph.

### Surgical Indications

Surgical intervention for uncomplicated LAS without associated fracture is reserved for cases with persistent symptoms and/or instability. Kerkhoffs et al. (25) found similar functional and subjective symptom outcomes when comparing surgical intervention versus conservative management of lateral ligament complex ankle injuries. High-grade syndesmosis injuries associated with significant tibiofibular diastasis or concurrent disruption of the deltoid ligament may benefit from surgical stabilization (26). Syndesmosis injury associated with malleolar fracture requires surgical stabilization of the bony fracture. However, concurrent repair of the syndesmosis injury is controversial (26).

In cases of chronic ankle instability, clinicians should consider other concurrent foot and ankle pathology before proceeding to surgery (Table 2). The modified Broström procedure is a commonly used surgical technique that involves the direct anatomic repair of injured lateral ligaments with reinforcement of the extensor retinaculum (27). Arthroscopy is commonly performed at the time of surgery to rule out concomitant intra-articular pathology.

We recommend triage to orthopedic surgery for consultation in the acute setting for unstable high ankle sprain, associated ankle fracture, as well as for cases of chronic refractory ankle instability that have not responded to standard of care (discussed below).



**Figure 2:** Ultrasound visualization of ruptured ATFL (top) compared to contralateral intact ATFL in the same individual (bottom).

**Table 2.**  
Diagnoses not to be missed.

Diagnosis	Clinical Findings	Diagnostics
Talar osteochondral lesion	Anterior joint line tenderness, recurrent effusion, persistent ankle pain worse with weightbearing and activity	MRI
Base of the fifth metatarsal fracture	Tenderness at the base of the fifth metatarsal	Plain radiographs
Anterior process of the calcaneus fracture	Tenderness over the anterior process of the calcaneus: halfway between lateral malleolus and base of the fifth metatarsal	MRI
Superficial peroneal nerve neuralgia	Weakness with ankle dorsiflexors, foot everters, and toe extensors. Sensory loss or paresthesia affecting anterolateral lower leg, dorsal foot, sparing the first dorsal web space	Electromyography
Peroneal tendon tears	Tenderness posterolateral ankle along peroneal tendon, weakness with ankle eversion	Ultrasound/MRI

Diagnoses not to be missed in patients who have persistent pain and instability in the setting of prior ankle sprain. Clinical presentation and suggested diagnostic imaging are described.

### Rehabilitation of Acute Ankle Sprain

#### *Rest, ice, compression, and elevation*

The initial focus of an acute ankle sprain rehabilitation program focuses on reducing pain while restoring strength and range of motion. Historically, clinicians have applied the principles of rest, ice, compression, and elevation (RICE) therapy near universally. However, the evidence supporting this approach is limited. Vuurberg et al. reviewed and pooled data from 33 randomized controlled trials studying the effect of cryotherapy in the treatment of acute ankle sprains and found no significant improvement in pain at rest, function, or swelling (12). A multicenter randomized controlled trial by Bendahou et al. compared the use of compression stockings versus noncompressive placebo stockings and found no significant difference in pain, analgesic consumption, or bimalleolar or midfoot circumference (28). There have been no controlled trials examining the use of rest or elevation alone in the treatment of acute ankle sprains. Nonetheless, the use of RICE therapy is a reasonable intervention in the acute phase of ankle sprain for short term symptomatic pain control to facilitate early mobilization.

Other modalities such as electrical stimulation and therapeutic ultrasound have been touted to aid in the recovery after acute ankle sprain; however, the current peer-reviewed literature does not support the use of these interventions in reducing pain, edema, or accelerating functional recovery after acute ankle sprain (29,30).

#### Nonsteroidal Anti-inflammatory Drug

Oral and topical nonsteroidal anti-inflammatory drugs (NSAID) may be a useful adjunct therapy in diminishing pain in the acute phase of ankle injury. NSAID act via cyclooxygenase inhibition and reduction of downstream production of prostaglandin and thromboxane; resulting in anti-inflammatory and analgesic effects (31). Although NSAID are generally regarded as safe, they should be used judiciously due to their potential for gastrointestinal, renal, and cardiovascular side effects (32). NSAID have been hypothesized to delay tissue healing due to inhibition of the normal inflammatory response to tissue injury (32). Acetaminophen is an equally effective alternative for reducing pain in the first 14 d after acute ankle sprain (12).

#### Immobilization and Bracing

In the management of acute LAS, evidence favors early mobilization and functional ankle support in the form of bracing or taping over rigid immobilization. Kerkhoffs et al. (33) found shorter time to return sport, greater reduction in swelling, and decreased radiographic evidence of instability with rehabilitation programs that included both early mobilization and functional ankle support compared to immobilization. Some investigators have found that a short period of immobilization (up to 10 d) may be beneficial for reducing pain and swelling (12). There are no randomized controlled trials studying immobilization in the initial management for medial or syndesmosis sprains; however, most experts suggest a period of immobilization and protected weight bearing up to 2 wk, due to concern that early range of motion may result in secondary injury (34,35).

#### Manual Therapy

The addition of manual therapy to a rehabilitation program for acute ankle sprains may provide benefits in pain reduction and functional recovery. Loudon et al. (36) reviewed eight controlled trials utilizing manual therapy and concluded that the application of manual therapy in the acute phase of ankle sprain injury resulted in improved ankle dorsiflexion, pain reduction, and improved stride length. Manual techniques reviewed in the study included A/P talocrural glides and talocrural distraction. These techniques call for the clinician to place the ankle in neutral position and apply a posteriorly directed force to the talus or attempt to distract the talus from the ankle mortise, respectively. Another randomized control trial by Cleland et al. found the addition of a manual therapy protocol to a physical therapy program resulted in greater improvements in Foot and Ankle Ability Measure, Lower Extremity Functional Scale, and pain scores in patients with acute LAS sustained at up to 6 months follow up (37). Based on these findings, we recommend the incorporation of manual therapy techniques into ankle sprain rehabilitation programs.

#### Neuromuscular Training

Neuromuscular and proprioceptive training programs are safe and effective additions to ankle rehabilitation programs that should be implemented as soon as tolerated after injury.

Altered neuromuscular activation patterns after ankle injury contribute to functional instability, alterations in gait, and elevate risk for recurrent injury (38). Early implementation of neuromuscular retraining within the first week of injury results in higher overall activity levels without increasing pain, swelling, or the rate of reinjury when compared with traditional RICE therapy (39). A systematic review and meta-analysis by Postle et al. (40) found proprioceptive exercises resulted in significant improvement in ankle functional outcome measures, such as the Star Excursion Balance Test and Functional Ankle Disability Index. Neuromuscular retraining programs reduce the prevalence of recurrent injury and functional instability (40–42). Therefore, we recommend early neuromuscular retraining for athletes who sustain an ankle sprain.

### Orthobiologics

To our knowledge, there have been no large-scale randomized controlled trials studying the effect of the platelet-rich plasma (PRP) injections in acute ankle sprains. There are two controlled trials studying the effect of PRP injection in acute syndesmosis sprains. Laver et al. (43) conducted a randomized controlled trial comparing a standard rehabilitation protocol to the same rehabilitation protocol supplemented by a single ultrasound-guided PRP injection to the AITFL and tibiofibular joint (43). They found faster return to play and lower pain scores in their intervention group. Samra et al. (44) treated rugby players with acute syndesmosis sprains using a single ultrasound guided PRP injection into the AITFL in addition to a standard rehabilitation protocol. They compared their intervention to a historical control group treated with standard rehabilitation alone. They found that the intervention group demonstrated faster return to play and greater improvements in functional measures. Both studies were limited by a small sample size ( $n = 8$  and  $n = 11$ , respectively). Further research is needed in this area.

### Prevention of Ankle Sprains and Recurrent Injury

#### *Bracing and taping*

Nonrigid ankle bracing and prophylactic ankle taping are both effective means for preventing first time and recurrent ankle sprains (12). These interventions have been shown to reduce the risk of sprains by 50% to 70% in those who have a history of ankle sprain (45). Although the effect size of these interventions is less pronounced in the prevention of primary ankle sprains, a recent large randomized control trial by McGuine et al. (46) demonstrated significant reductions in both primary and recurrent ankle sprains in high school basketball players who were provided nonrigid lace up ankle braces. When compared head to head, bracing and taping perform similarly; however, cost analysis favors bracing significantly over taping (47). Both appear to be effective interventions in preventing first time or recurrent ankle sprain, and the choice may be based on athlete preference. There are no trials comparing the simultaneous use of both tape and bracing to either taping or bracing alone. We recommend lace up ankle brace or taping for 1 year after ankle sprain to prevent recurrent injury.

### Neuromuscular Training Programs

Neuromuscular training programs typically include balance and proprioception tasks with recurrent voluntary or involuntary destabilization during exercise. These programs improve ankle joint position sense, muscle reaction time, and functional outcome scores (42). They reduce the rate of recurrent ankle sprains up to 12 months after acute ankle sprain and should be started in all athletes who sustain an ankle sprain as soon as tolerated after injury (12).

Although effective for prevention of recurrent sprains, the evidence for reducing the rate of first-time ankle sprains with neuromuscular training programs is less robust. Foss et al. (48) performed a prospective randomized control study implementing a neuromuscular training program among middle school and high school aged athletes and found reduced overall injury rates, but no significant difference in ankle injuries specifically.

### Return-to-Play Considerations

Ideally, athletes may return to play when he or she has full, painless range of motion and strength is restored. The athlete should be able to complete sport specific activities without recurrent symptoms. Although ligament healing time may require a period of 6 to 12 wk, time to return to sport varies greatly (49). Observational studies show 90% of high school athletes with either first time or recurrent ankle sprain returned to play within 1 wk, far shorter than the demonstrated time for physiologic ligament healing (50). Because the natural history of ankle sprain injury is for rapid reduction in pain in the first 2 wk, a corresponding reduction in perceived disability may result in early return to play with inadequate rehabilitation (7). Moreover, AITFL sprain requires significantly longer time to return to play than LAS.

### Conclusions

Ankle sprains are common injuries that require thorough evaluation and evidence-driven interventions to promote an expedited and complete recovery. At the time of initial injury, we recommend the application of the Ottawa Ankle to assess risk of fracture and reduce unnecessary radiographs. Modalities, such as RICE therapy, electrical stimulation, NSAID, and Tylenol, do not accelerate recovery, but are reasonable interventions for short term pain reduction. We favor early mobilization after acute lateral sprain as it has been shown to accelerate return to play and introduce early neuromuscular training programs in all athletes with ankle sprains to reduce the risk of recurrent sprain. In addition, nonrigid ankle bracing for 1 year after ankle sprain is recommended for prevention of recurrent sprain. Finally, we endorse surgical referral and consideration of stabilization for cases of chronic ankle instability that do not respond to nonoperative measures after concomitant pathologies have been ruled out.

The authors declare no conflict of interest and do not have any financial disclosures.

### References

1. Waterman BR, Owens BD, Davey S, et al. The epidemiology of ankle sprains in the United States. *J. Bone Jt Surg—Ser A.* 2010; 92:2279–84.
2. Roos KG, Kerr ZY, Mauntel TC, et al. The epidemiology of lateral ligament complex ankle sprains in National Collegiate Athletic Association Sports. *Am. J. Sports Med.* 2017; 45:201–9.

3. Mauntel TC, Wikstrom EA, Roos KG, *et al.* The epidemiology of high ankle sprains in National Collegiate Athletic Association Sports. *Am. J. Sports Med.* 2017; 45:2156–63.
4. Kopec TJ, Hibberd EE, Roos KG, *et al.* The epidemiology of deltoid ligament sprains in 25 National Collegiate Athletic Association Sports, 2009–2010 through 2014–2015 academic years. *J. Athl. Train.* 2017; 52:350–9.
5. Gribble PA, Bleakley CM, Caulfield BM, *et al.* Evidence review for the 2016 international ankle consortium consensus statement on the prevalence, impact and long-term consequences of lateral ankle sprains. *Br. J. Sports Med.* 2016; 50: 1496–505.
6. Verhagen E, van Tulder M, van der Beek AJ, *et al.* An economic evaluation of a proprioceptive balance board training programme for the prevention of ankle sprains in volleyball. *Br. J. Sports Med.* 2005; 39:111–5.
7. van Rijn RM, van Os AG, Bernsen RM, *et al.* What is the clinical course of acute ankle sprains? A systematic literature review. *Am. J. Med.* 2008; 121: 324–331.e6.
8. Delahunty E, Coughlan GF, Caulfield B, *et al.* Inclusion criteria when investigating insufficiencies in chronic ankle instability. *Med. Sci. Sports Exerc.* 2010; 42: 2106–21.
9. Golanó P, Vega J, de Leeuw PA, *et al.* Anatomy of the ankle ligaments: a pictorial essay. *Knee Surgery, Sport Traumatol Arthrosc.* 2016; 24:944–56.
10. Van Den Bekerom MP, Oostra RJ, Alvarez PG, Van Dijk CN. The anatomy in relation to injury of the lateral collateral ligaments of the ankle: a current concepts review. *Clin. Anat.* 2008; 21:619–26.
11. Fong DT-P, Hong Y, Chan L-K, *et al.* A systematic review on ankle injury and ankle sprain in sports. *Sports Med.* 2007; 37:73–94.
12. Vuurberg G, Hoorntje A, Wink LM, *et al.* Diagnosis, treatment and prevention of ankle sprains: update of an evidence-based clinical guideline. *Br. J. Sports Med.* 2018; 1–15.
13. Kobayashi T, Tanaka M, Shida M. Intrinsic risk factors of lateral ankle sprain. *Sport Heal A Multidiscip Approach.* 2016; 8:190–3.
14. Doherty C, Delahunty E, Caulfield B, *et al.* The incidence and prevalence of ankle sprain injury: a systematic review and meta-analysis of prospective epidemiological studies. *Sports Med.* 2014; 44:123–40.
15. Mengiardi B, Zanetti M. Medial supporting structures of the ankle: part I medial collateral ligament complex of the ankle: MR anatomy and MR findings in medial instability. *Semin. Musculoskelet. Radiol.* 2016; 20:91–103.
16. McCollum GA, van den Bekerom MP, Kerkhoffs GM, *et al.* Syndesmosis and deltoid ligament injuries in the athlete. *Knee Surgery, Sport Traumatol Arthrosc.* 2013; 21:1328–37.
17. Hunt KJ, Phisitkul P, Pirolo J, Amendola A. High ankle sprains and syndesmosis injuries in athletes. *J. Am. Acad. Orthop. Surg.* 2015; 23:661–73.
18. Beckenkamp PR, Lin CC, Macaskill P, *et al.* Diagnostic accuracy of the Ottawa ankle and Midfoot rules: a systematic review with meta-analysis. *Br. J. Sports Med.* 2017; 51:504–10.
19. Malanga G, Mautner K. *Musculoskeletal Physical Examination: An Evidence-based Approach.* 2nd ed. Elsevier, Inc; 2017. p. 199–217.
20. Mitsiokapa E, Mavrogenis AF, Drakopoulos D, *et al.* Peroneal nerve palsy after ankle sprain: an update. *Eur. J. Orthop Surg Traumatol.* 2017 Jan 31; 27:53–60.
21. Polzer H, Kanz KG, Prall WC, *et al.* Diagnosis and treatment of acute ankle injuries: development of an evidence-based algorithm. *Orthop. Rev. (Pavia).* 2011; 4:5.
22. Stufkens SA, van den Bekerom MP, Knupp M, *et al.* The diagnosis and treatment of deltoid ligament lesions in supination-external rotation ankle fractures: a review. *Strateg Trauma Limb Reconstr.* 2012; 7:73–85.
23. Alves T, Dong Q, Jacobson J, *et al.* Normal and injured ankle ligaments on ultrasonography with magnetic resonance imaging correlation. *J. Ultrasound Med.* 2018; 1–16.
24. Lee SH, Yun SJ. The feasibility of point-of-care ankle ultrasound examination in patients with recurrent ankle sprain and chronic ankle instability: comparison with magnetic resonance imaging. *Injury.* 2017; 48:2323–8.
25. Kerkhoffs GM, Handoll HH, de Bie R, *et al.* Surgical versus conservative treatment for acute injuries of the lateral ligament complex of the ankle in adults. *Cochrane Database Syst. Rev.* 2007; 18:CD000380.
26. Switaj PJ, Mendoza M, Kadakia AR. Acute and chronic injuries to the syndesmosis. *Clin. Sports Med.* 2015; 34:643–77.
27. Shakked RJ, Karnovsky S, Drakos MC. Operative treatment of lateral ligament instability. *Curr. Rev. Musculoskelet. Med.* 2017; 10:113–21.
28. Bendahou M, Khiami F, Saïdi K, *et al.* Compression stockings in ankle sprain: a multicenter randomized study. *Am. J. Emerg. Med.* 2014; 32:1005–10.
29. Feger MA, Goetschius J, Love H, *et al.* Electrical stimulation as a treatment intervention to improve function, edema or pain following acute lateral ankle sprains: a systematic review. *Phys. Ther. Sport.* 2015; 16:361–9.
30. van den Bekerom MP, van der Windt DA, Ter Riet G, *et al.* Therapeutic ultrasound for acute ankle sprains. *Cochrane Database Syst. Rev.* 2011; 15: CD001250.
31. Struijs PA, Kerkhoffs GM. Ankle sprain: the effects of non-steroidal anti-inflammatory drugs. *BMJ Clin Evid.* 2015; 28:2015.
32. Stovitz SD, Johnson RJ. NSAIDs and musculoskeletal treatment: what is the clinical evidence? *Phys. Sportsmed.* 2003; 31:35–52.
33. Kerkhoffs GM, Rowe BH, Assendelft WJ, *et al.* Immobilisation and functional treatment for acute lateral ankle ligament injuries in adults. *Cochrane Database Syst. Rev.* 2013; 28:CD003762.
34. Knapik DM, Trem A, Sheehan J, *et al.* Conservative management for stable high ankle injuries in professional football players. *Sports Health.* 2018; 10:80–4.
35. Nussbaum ED, Hosea TM, Sieler SD, *et al.* Prospective evaluation of syndesmosis ankle sprains without diastasis. *Am. J. Sports Med.* 2001; 29:31–5.
36. Loudon JK, Reiman MP, Sylvain J. The efficacy of manual joint mobilisation/manipulation in treatment of lateral ankle sprains: a systematic review. *Br. J. Sports Med.* 2014; 48:365–70.
37. Cleland JA, Mintken P, McDevitt A, *et al.* Manual physical therapy and exercise versus supervised home exercise in the management of patients with inversion ankle sprain: a multicenter randomized clinical trial. *J. Orthop Sport Phys Ther.* 2013; 43:443–55.
38. Punt IM, Ziltener JL, Laidet M, *et al.* Gait and physical impairments in patients with acute ankle sprains who did not receive physical therapy. *PM R.* 2015; 7: 34–41.
39. Bleakley CM, O'Connor SR, Tully M, *et al.* Effect of accelerated rehabilitation on function after ankle sprain: randomised controlled trial. *BMJ.* 2010; 340:c1964.
40. Postle K, Pak D, Smith TO. Effectiveness of proprioceptive exercises for ankle ligament injury in adults: a systematic literature and meta-analysis. *Man. Ther.* 2012; 17:285–91.
41. van der Wees PJ, Lencsen AF, Hendriks EJ, *et al.* Effectiveness of exercise therapy and manual mobilisation in ankle sprain and functional instability: a systematic review. *Aust. J. Physiother.* 2006; 52:27–37.
42. Zech A, Hübscher M, Vogt L, *et al.* Neuromuscular training for rehabilitation of sports injuries: a systematic review. *Med. Sci. Sports Exerc.* 2009; 41:1831–41.
43. Laver L, Carmont MR, McConkey MO, *et al.* Plasma rich in growth factors (PRGF) as a treatment for high ankle sprain in elite athletes: a randomized controlled trial. *Knee Surgery, Sport Traumatol Arthrosc.* 2015; 23:3383–92.
44. Samra DJ, Sman AD, Rae K, *et al.* Effectiveness of a single platelet-rich plasma injection to promote recovery in rugby players with ankle syndesmosis injury. *BMJ Open Sport Exerc. Med.* 2017; 3:1–7.
45. McKeon PO, Mattacola CG. Interventions for the prevention of first time and recurrent ankle sprains. *Clin. Sports Med.* 2008; 27:371–82.
46. McGuine TA, Brooks A, Hetzel S. The effect of lace-up ankle braces on injury rates in high school basketball players. *Am. J. Sports Med.* 2011; 39:1840–8.
47. Janssen KW, Hendriks MR, Van Mechelen W, Verhagen E. The cost-effectiveness of measures to prevent recurrent ankle sprains: results of a 3-arm randomized controlled trial. *Am. J. Sports Med.* 2014; 42:1534–41.
48. Foss KDB, Thomas S, Khoury JC, *et al.* A school-based neuromuscular training program and sport-related injury incidence: a prospective randomized controlled clinical trial. *J. Athl. Train.* 2018; 53:20–8.
49. Hubbard TJ, Hicks-Little CA. Ankle ligament healing after an acute ankle sprain: an evidence-based approach. *J. Athl. Train.* 2008; 43:523–9.
50. Medina McKeon JM, Bush HM, Reed A, *et al.* Return-to-play probabilities following new versus recurrent ankle sprains in high school athletes. *J. Sci. Med. Sport.* 2014; 17:23–8.